CHAPTER 32

Spinal Injury and Spine Motion Restriction

The following items provide an overview to the purpose and content of this chapter. The Standard and Competency are from the National EMS Education Standards.

STANDARD • Trauma (Content Area: Head, Facial, Neck, and Spine Trauma)

COMPETENCY • Applies fundamental knowledge to provide basic emergency care and transportation based on assessment findings for an acutely injured patient.

OBJECTIVES • After reading this chapter, you should be able to:

32-1. Define key terms introduced in this chapter.
32-2. Review the anatomy and physiology of the spinal column, spinal cord, and tracts within the spinal column.
32-3. Discuss common mechanisms that may result in spinal column or spinal cord injury.
32-4. Delineate between spinal column injury and spinal cord injury.
32-5. Discuss the pathophysiology underlying different types of cord injury, including both complete and incomplete spinal cord syndromes.
32-6. List the indications for transporting a trauma patient with spine motion restriction precautions in place.
32-7. Describe the assessment of pulse, motor function, and sensory function of a patient suspected of having an injury to the spine, and delineate between normal and abnormal findings.
32-8. Explain the assessment-based approach to spinal cord injury, including the incorporation of assessment findings into a field impression and the appropriate prehospital emergency care.
32-9. Delineate between spine motion restriction techniques and the historical approach of spinal immobilization techniques.
32-10. List and discuss the criteria often used to determine if spinal motion restriction precautions can be withheld on a trauma patient.
32-11. Describe the guidelines and process for using spine motion restriction devices such as a cervical collar, full body device, short spine device, and supplemental SMR equipment.
32-12. List the procedural steps for providing spine motion restriction techniques to the ambulatory patient.
32-13. List the procedural steps for providing spine motion restriction techniques to a patient seated in a vehicle, including the rapid rollout process.
32-14. Explain spine motion restriction considerations when spinal injury is suspected for a patient wearing a helmet or for an infant in a car seat.

KEY TERMS • Page references indicate the first major use in this chapter. For complete definitions, see the Glossary at the back of this book.

anterior cord syndrome *p. 954*
Brown-Séquard syndrome *p. 954*
central cord syndrome *p. 953*
cervical spine *p. 949*
coccyx *p. 949*
complete spinal cord injury *p. 952*
disk *p. 949*
incomplete spinal cord injury *p. 953*
light touch tracts *p. 950*
lumbar spine *p. 949*
motor tracts *p. 950*
neurogenic hypotension *p. 953*
pain tracts *p. 950*
priapism *p. 952*
sacral spine *p. 949*
self-restriction *p. 956*
spinal column *p. 949*
spinal cord *p. 949*
spinal shock *p. 952*
spine motion restriction (SMR) *p. 952*
thoracic spine *p. 949*
vertebrae *p. 949*

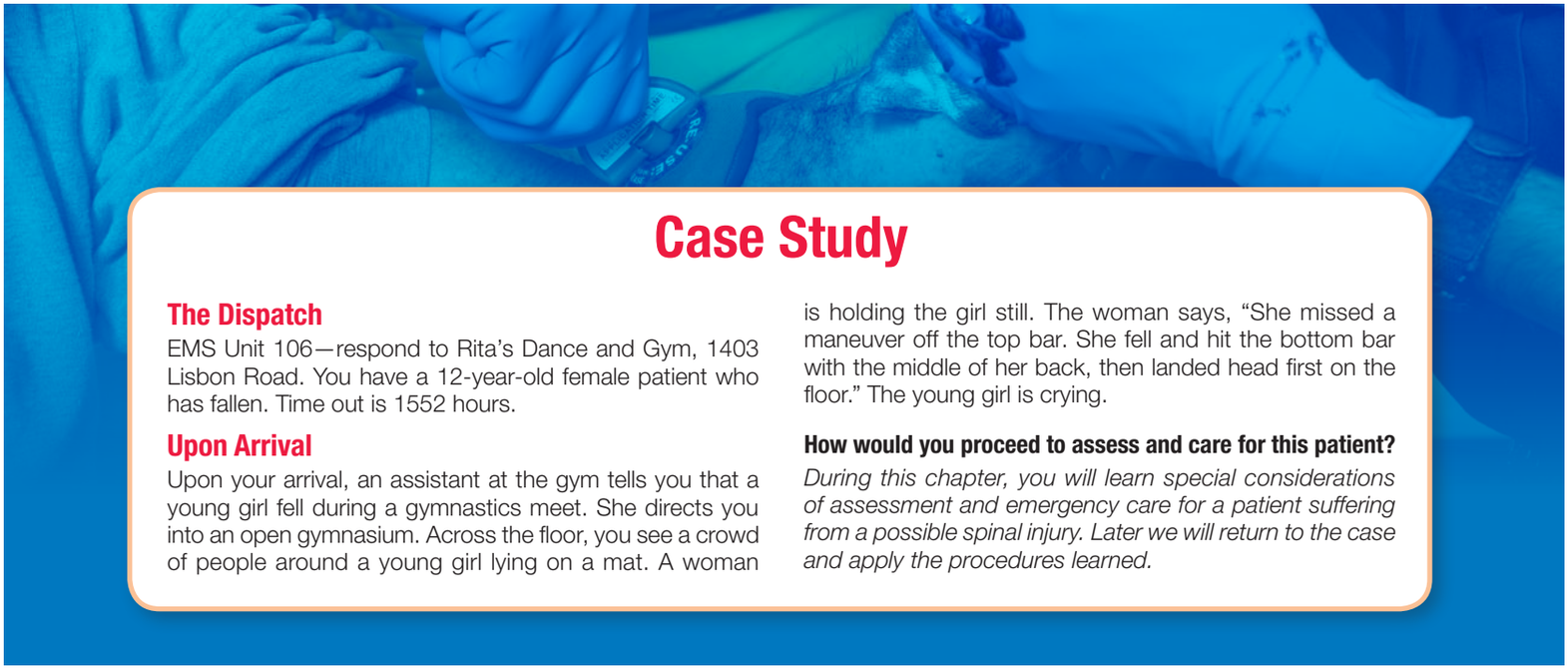

Case Study

The Dispatch

EMS Unit 106—respond to Rita's Dance and Gym, 1403 Lisbon Road. You have a 12-year-old female patient who has fallen. Time out is 1552 hours.

Upon Arrival

Upon your arrival, an assistant at the gym tells you that a young girl fell during a gymnastics meet. She directs you into an open gymnasium. Across the floor, you see a crowd of people around a young girl lying on a mat. A woman is holding the girl still. The woman says, "She missed a maneuver off the top bar. She fell and hit the bottom bar with the middle of her back, then landed head first on the floor." The young girl is crying.

How would you proceed to assess and care for this patient?

During this chapter, you will learn special considerations of assessment and emergency care for a patient suffering from a possible spinal injury. Later we will return to the case and apply the procedures learned.

INTRODUCTION

Spine injuries are among the most formidable and traumatic you will manage as an EMT. Yet you might face the probability of such injuries on almost a daily basis. Automobile crashes, shallow-water diving accidents, motorcycle crashes, and falls are common causes of spinal injury. Likewise, accidents during skiing, sledding, football, and gymnastics can result in spinal injury. It is your job as an EMT to recognize injuries that could damage the spinal column or spinal cord and provide appropriate emergency care. You must be aware that improper movement and handling of patients in such situations can lead to permanent disability or even death.

ANATOMY AND PHYSIOLOGY OF SPINAL INJURY

To appreciate the potential severity of spine injuries, you should begin by understanding the relationship between the nervous system and the parts of the skeletal system most closely related to it: the skull and the spinal column, also referred to as the vertebral column. Before continuing, you might want to review the information about the skeletal and nervous systems that was presented in the "Anatomy, Physiology, and Medical Terminology" chapter, in the "Musculoskeletal Trauma and Nontraumatic Fractures" chapter, and in the "Head Trauma" chapter.

The Nervous System

Injuries to the spine have the potential for severity because within the spinal column is the spinal cord. This structure carries nerve impulses from most of the body to the brain and back to the body. A single spinal cord injury can affect several organs and body functions.

Parts of the Nervous System

The nervous system has two major functions: communication and control. It enables the individual to be aware of and react to his environment. It also coordinates the responses of the body to changes in the environment and keeps body systems working together.

The nervous system consists of nerve centers and nerves that branch off from the centers and lead to tissues and organs. Most nerve centers are in the brain and spinal cord.

The structural divisions of the nervous system (Figure 32-1 ■) are:

- The *central nervous system (CNS)*, which consists of the brain and the spinal cord.
- The *peripheral nervous system*, which consists of nerves located outside of the brain and spinal cord.

The functional divisions of the nervous system are:

- The *voluntary nervous system*, which influences the activity of voluntary (skeletal) muscles and movements throughout the body.
- The *autonomic nervous system*, which is automatic and influences the activities of involuntary muscles and glands; the autonomic system is partly independent of the rest of the nervous system. The sympathetic nervous system and parasympathetic nervous system are included in the autonomic nervous system.

The Skeletal System

The *skeletal system* gives the body its framework, supports and protects vital organs, and permits motion. The bony framework of the body is held together by *ligaments*—tough, fibrous connective tissue. The skeleton is flexible enough to absorb and protect against

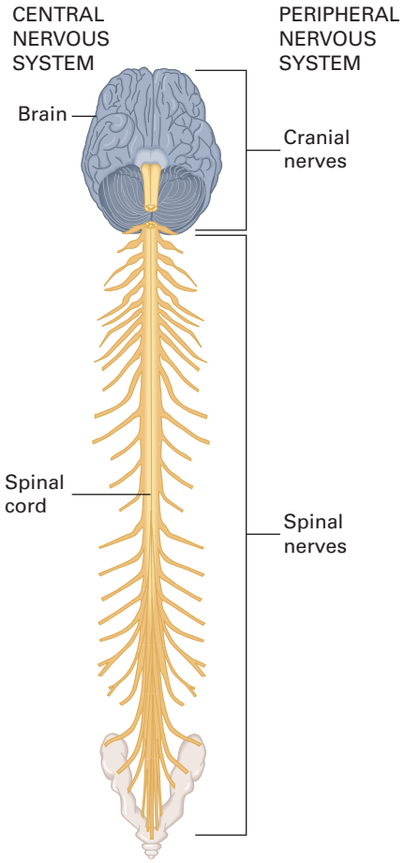

■ **FIGURE 32-1** Components of the central and peripheral nervous systems.

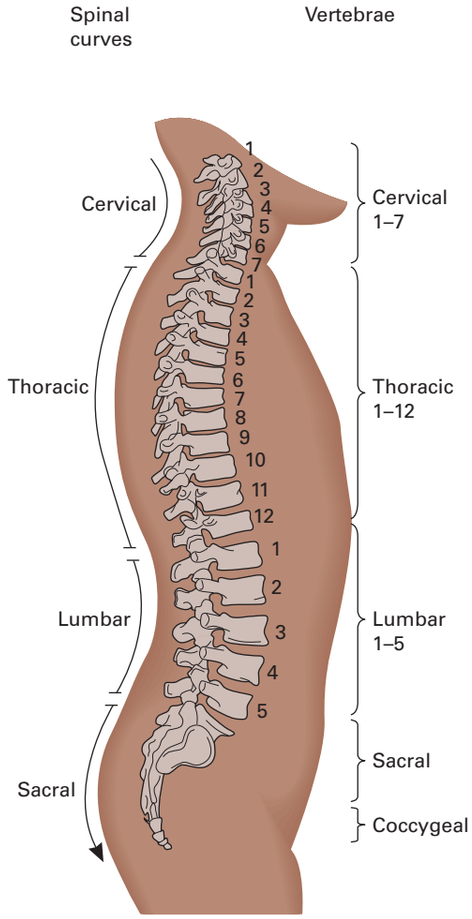

■ **FIGURE 32-2** The spinal (vertebral) column.

impacts and stress. The parts of the skeletal system that protect the most important parts of the nervous system are the skull and the spinal column.

The Skull

Resting at the top of the spinal column, the skull contains the brain. The skull has two parts: the cranium (or braincase) and the face.

The Spinal Column

The **spinal column**, or *vertebral column,* is the principal support system of the body. Ribs originate from it to form the thoracic cavity, and the rest of the skeleton is directly or indirectly attached to the spine.

Amazingly mobile, the spinal column consists of 33 irregularly shaped bones called **vertebrae**. The *body* of a vertebra is the bulky portion that faces anteriorly in the spinal column. The posterior aspect of a vertebra is the *spinous process*. The spinous processes can be felt as the bony projections along the spinal column. Lying one on top of the other to form a strong, flexible column, the vertebrae are bound firmly together by strong ligaments. Between each two vertebrae is a fluid-filled pad of tough elastic cartilage called a **disk** that acts as a shock absorber. The spinal column, which surrounds and protects the spinal cord, is divided into five parts (Figure 32-2 ■):

- **Cervical spine.** The first seven vertebrae that form the neck. The cervical vertebrae are the most mobile and delicate; injury to the cervical spine is the most common cause of spinal cord injury.
- **Thoracic spine.** The 12 vertebrae directly below the cervical vertebrae that compose the upper back.
- **Lumbar spine.** The next five vertebrae that form the lower back.
- **Sacral spine** (sacrum). The next five vertebrae that are fused together and form the rigid posterior portion of the pelvis.
- **Coccyx** (tailbone). The four fused vertebrae that form the lower end of the spine.

The **spinal cord**, composed of nervous tissue, exits the brain through an opening at the base of the skull.

The cord is surrounded by a sheath of protective membranes (meninges) and a cushioning layer of cerebrospinal fluid. The cord narrows as it goes, filling 95 percent of the spinal column "canal" in the cervical vertebrae (neck) but only 60 percent in the lumbar area (lower back). All nerves to the trunk and extremities originate from the spinal cord. The spinal cord carries messages from the brain to the various parts of the body through nerve bundles.

Three main types of tracts within the spinal cord are tested in the assessment to determine if spinal cord injuries exist. The **motor tracts** carry impulses down the spinal cord and out to muscles. As their name implies, motor tracts are tested by having the patient move. The motor tracts on the right side of the spinal cord carry the impulses that enable the patient to move on the right side of the body; the motor tracts on the left side enable movement on the left side of the body.

The **pain tracts** carry impulses from pain receptors up the spinal cord to the brain. The pain tracts are tested by applying pain to the patient. Upon entering the spinal cord, a pain tract crosses over and carries the impulse up the opposite side of the cord. Thus, pain applied to the right side of the body is carried up the left side of the spinal cord. To test the right pain tract in the spinal cord, you must apply pain to the left side of the body; to test the left pain tract, apply pain to the right side of the body.

The last set of tracts carry light touch impulses from sensory receptors up the spinal cord to the brain. The **light touch tracts** are tested by applying light touch to the patient. The light touch sensation is carried up the same side of the spinal cord as the side where the touch is applied. If you apply light touch to the right side of the body, the light touch is carried up the right side of the spinal cord; light touch applied to the left side of the body is carried up the left side of the cord.

Because light touch and pain are carried by different tracts, the patient might not feel light touch but can feel the pain of a pinch. This finding can be present if the spinal cord is partially but not completely injured.

Studying the spinal cord tracts to understand where they are located and what impulses are carried by them can help you better understand assessment findings associated with incomplete spinal cord injuries, which are discussed later in the chapter. Also, knowing that various tracts within the spinal cord carry different impulses can reinforce and help you better understand the steps in the neurologic assessment.

PATHOPHYSIOLOGY PEARLS

Motor and light touch tracts carry the impulse on the same side of the spinal cord as the extremity that is tested, whereas pain is carried up the opposite side of the spinal cord from the extremity the pain is applied to. This might create conflicting assessment findings in the incomplete spinal cord injury. ■

ASSESSMENT TIPS

You cannot assume that just because a patient cannot feel light touch he also cannot feel pain because light touch and pain sensations are carried by different spinal tracts. ■

Common Mechanisms of Spinal Injury

The most common cause of spinal injuries is automobile crashes. These cause approximately one-half (48 percent) of all spinal injuries. The next most common cause is falls (21 percent). Gunshot wounds and recreational activities such as diving and football are the next most-frequent causes of spinal injuries. Any patient with a gunshot wound to the neck; the anterior, lateral, or posterior chest; the abdomen; or the pelvis must be assessed for spinal injury.

It is important to note that only 14–15 percent of patients who have spinal column fractures or dislocations have a spinal cord injury that results in neurologic deficits (motor or sensory dysfunction). This means that 85–86 percent of the patients who have a spinal fracture or dislocation do not present with a neurologic deficit. When you arrive on the scene and find the patient walking about, it does not mean the patient did not suffer a spinal injury. The patient could have suffered a spinal column injury with no spinal cord involvement. Improper management of this patient, however, can convert a spinal column injury into a spinal cord injury. The result, which might be permanent paralysis, is catastrophic. Conversely, a patient can have a spinal cord injury without any spinal (vertebral) column damage. This specific condition is referred to as a spinal cord injury without radiologic abnormality or SCIWORA. Do not become complacent in the management of any patient with a significant mechanism of injury (MOI) for spinal trauma or one who displays any signs or symptoms of spinal column or cord injury.

Elderly patients often suffer fractures much more easily with less force applied to the spine. C1 and C2 dislocations might be more common in elderly patients who suffer from rheumatoid arthritis and might be more common in Down syndrome patients because of abnormal development of the odontoid (second cervical vertebra).

The spine is quite strong and flexible, but it is particularly susceptible to injury from the following mechanisms (Figure 32-3 ■):

- **Compression.** When the weight of the body is driven against the head. This is common in falls, diving accidents, motor vehicle crashes, or other accidents in which a person impacts an object head first.
- **Flexion.** When there is severe forward movement of the head in which the chin meets the chest, or when the torso is excessively curled forward.
- **Extension.** When there is severe backward movement of the head in which the neck is stretched, or when the torso is severely arched backward.

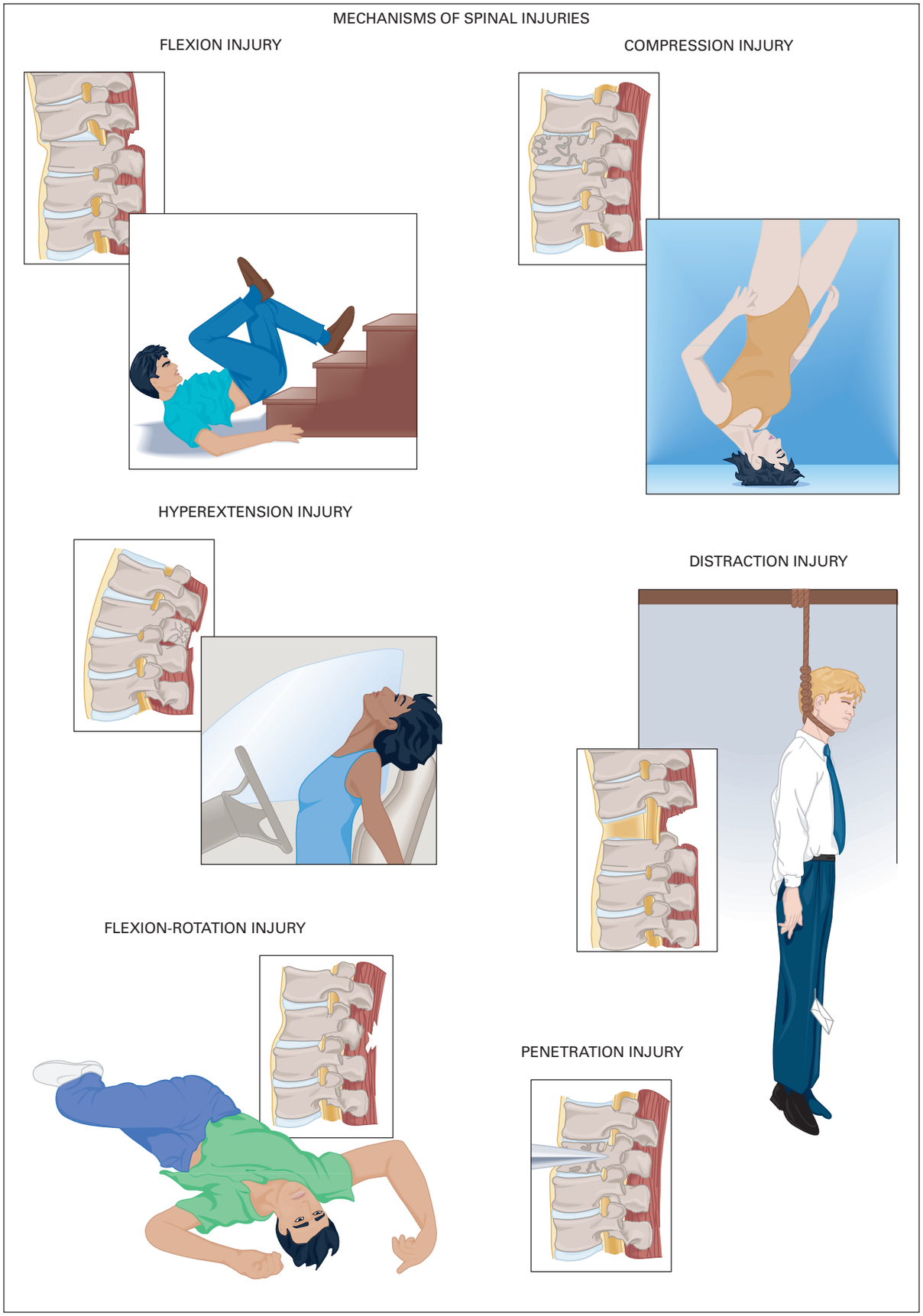

■ **FIGURE 32-3** Mechanisms of spinal injury.

- **Rotation.** When there is lateral movement of the head or spine beyond its normal rotation.
- **Lateral bending.** When the body or neck is bent severely from the side.
- **Distraction.** When the vertebrae and spinal cord are stretched and pulled apart. This is common in hangings.
- **Penetration.** When there is injury from gunshots, stabbings, or other types of penetrating trauma that involve the cranium or spinal column.

You must suspect spinal injury in any case that might involve one or more of these mechanisms, even if the patient appears to move normally. Injured vertebrae that are still aligned, but unstable, can become unstable at any moment and damage or sever the spinal cord. Conduct a thorough assessment to determine if spinal injury is suspected and the need for **spine motion restriction (SMR)**, steps to keep the spine in anatomic alignment and to restrict its movement, which are discussed in detail later in this chapter.

Spinal Column Injury Versus Spinal Cord Injury

A *spinal column injury* is an injury to one or more vertebrae, that is, the portion of the spine composed of bone. Whether it is a fracture or a dislocation, a spinal column injury is a bone injury. One thing we know about fractures and dislocations is that they hurt! If a patient has an injury to the spinal (vertebral) column, which is the bony portion of the spine, it can produce a complaint of pain or tenderness somewhere along the spine. Remember, pain is what the patient complains of, and tenderness is pain elicited on palpation. You must gently palpate the length of the spine, feeling for any gross abnormalities, while also checking for tenderness. If at any point the patient complains of pain or tenderness along the length of the spinal column, it is an indication of potential injury. You must perform spine motion restriction, which is described later in the chapter.

A *spinal cord injury* involves damage to the nervous tissue that is enclosed inside the hollow center of the bony spinal column: the spinal cord. As discussed previously, the spinal cord contains motor tracts that transmit impulses from the brain that cause muscle movement, and sensory tracts that transmit impulses of light touch, pain, and pressure to the brain. If the spinal cord is injured, a disruption in one or more of the motor or sensory tracts is likely. Thus, the patient with a spinal cord injury would experience a loss of motor or sensory function or both.

Although a patient complaining of pain to the spinal column likely has a vertebral (spinal column) fracture or injury. A patient could have a vertebral injury without a spinal cord injury. Conversely, a loss of motor or sensory function indicates a spinal cord injury; however, it does not imply a vertebral fracture or injury. This is because a spinal column injury can occur without a spinal cord injury, and a spinal cord injury can occur without a spinal column injury. Therefore, a patient might experience a loss of motor or sensory function but have no pain. Or the patient might complain of pain but have no loss of motor or sensory function. In either case—pain/tenderness along the spinal column or loss of motor/sensory function—the patient would be considered to have a spinal injury and must have spine motion restriction applied.

Complete Spinal Cord Injury

A **complete spinal cord injury** results when an area of the spinal cord has been completely transected (cut crossways) either physically or physiologically. The injury, having severed the motor and sensory tracts, prevents any motor impulses from passing down from brain to body or sensory impulses from passing up from body to brain through the injured area of the cord. Therefore, there is a total loss of motor and sensory function below the level of injury. The patient presents with the inability to move or feel sensations of pain, light touch, and crude pressure below the level of injury. The patient can also likely present with a loss of bowel and bladder control because autonomic function is blocked.

When a patient presents with complete loss of motor and sensory function distal to the cord injury, however, it might not always indicate complete spinal cord injury. The patient might, instead, be experiencing spinal shock.

Spinal Shock

Spinal shock is a temporary concussion-like insult to the spinal cord that causes effects below the level of the injury. Such an injury usually occurs high in the cervical region. Below the level of injury, there is a loss of muscle tone (flaccid muscles), the patient cannot feel sensations of light touch or pinch (anesthetic effect), and the patient cannot move the extremities or any voluntary muscles (paralysis). The patient typically loses control of the bladder and bowel. A male patient might have an involuntary erection of the penis called **priapism**. The vessels below the site of injury might dilate, leading to a decreased blood pressure (neurogenic hypotension, explained in the next section). Temperature regulation is also disrupted by the loss of vessel tone.

Spinal shock usually resolves within 24 hours after the incident but can last for several days. This patient should be managed as one with a spinal injury, even if the dysfunction begins to resolve while you are managing the patient.

ASSESSMENT TIPS

A patient in spinal shock can present with complete paralysis that might resolve within 24 hours to several days after the injury. ■

Neurogenic Hypotension from Spinal Shock. **Neurogenic hypotension** from spinal shock, also called *spinal-vascular shock* or *neurogenic shock*, results from an injury to the spinal cord that interrupts nerve impulses to the arteries. When the arteries lose nervous impulses from the brain and spinal cord, they relax and dilate (enlarge). This vasodilation causes a relative hypovolemia within the circulatory system. That is, there is more space than there is blood to fill the arteries. Because of this, the patient becomes hypotensive (has lowered blood pressure).

With spinal shock, sympathetic nerve impulses to the adrenal glands are lost, which prevents the release of epinephrine and norepinephrine. This causes vasodilation, which presents in the assessment as red or flushed skin, and a lack of sweat gland stimulation causing the skin to remain dry. With the blood pooling in the periphery and the lack of circulating hormones (epinephrine and norepinephrine), the patient's physical signs are different from those of classic hypovolemic shock (shock from fluid loss). Instead of pale, moist skin as would develop with hypovolemia, the spinal shock patient's skin will be warm and dry and appear flushed or red. In spinal shock, in which sympathetic impulses are impaired, the patient's pulse is typically 60–80 beats per minute. This differs from the rapid rates that usually result from sympathetic nervous system stimulation in hypovolemia. Neurogenic shock and hypovolemic shock can occur together, but the classic findings of hypovolemic shock may be masked by the spinal cord injury.

Treatment for spinal shock is much the same as for any other shock. Spine motion restriction must be applied, and the patient must be kept warm because of the increased heat loss from the peripheral vasodilation.

Incomplete Spinal Cord Injury

Incomplete spinal cord injury occurs when the spinal cord is injured—but not completely through all the three major tracts (motor, light touch, and pain tracts). That means that some of the tracts are spared and retain function. Because some tracts are injured and some are not, the patient might present with conflicting or confusing signs of spinal cord injury. Some of the spinal cord is not injured; therefore, some function is retained. The patient might not move some areas of the body and not move other areas of the body, or the patient might retain the sensation of pain to some areas of the body but not to others. Unlike a complete spinal cord injury, which causes complete loss of motor and sensory function below the level of injury, the incomplete spinal cord injury produces only loss of some function in some areas of the body.

The three most common types of incomplete spinal cord injury result in distinctive patterns of signs and symptoms (syndromes). They are central cord syndrome, anterior cord syndrome, and Brown-Séquard syndrome.

Central Cord Syndrome. If the central portion of the spinal cord is injured (Figure 32-4a ■), the patient might present with weakness or paralysis and loss of pain sensation to the upper extremities while the lower extremities have good function. This is opposite to what is expected in a patient with a complete spinal cord injury, which is loss of function below the site of injury. The reason for the loss of function in the upper extremities and not the lower is that the medial (inner) aspects of the motor and pain tracts control the upper extremities, whereas the lateral (outer) portions of the tracts control the lower extremities. In **central cord syndrome**, the medial or middle portion of the spinal cord is injured, causing a dysfunction in the inner tracts that control upper extremity motor and sensory function. Central cord syndrome is more commonly seen in elderly patients.

ASSESSMENT TIPS

In central cord syndrome, the patient presents with a loss of motor function or weakness and loss of pain sensation to the upper extremities while motor and sensory function remain normal in the lower extremities. ■

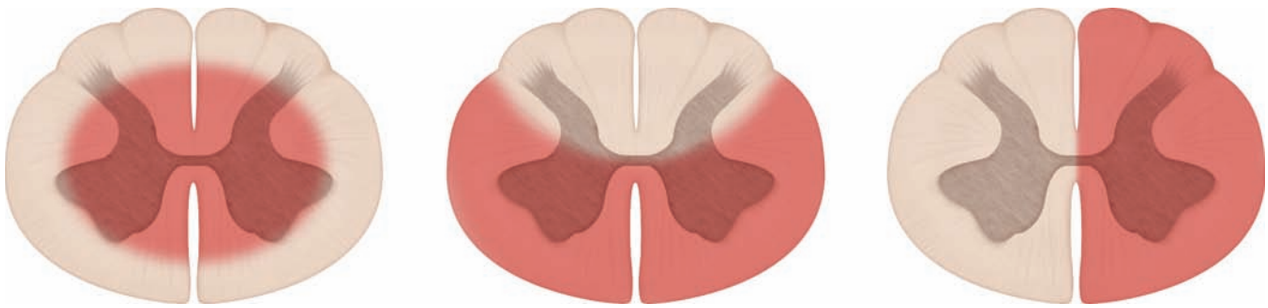

(a) Central cord syndrome (b) Anterior cord syndrome (c) Brown-Séquard syndrome

■ **FIGURE 32-4** Cross sections of the spinal cord showing the H-shaped gray matter surrounded by white matter. Illustrated here are the three most common types of incomplete spinal cord injury. (The areas of injury are highlighted in red.) Each results in a distinctive syndrome, or pattern of sensory and motor deficits. **(a)** Central cord syndrome results from injury to the central cord. **(b)** Anterior cord syndrome results from injury to the anterior cord. **(c)** Brown-Séquard syndrome results from injury to the right or left half of the cord.

Anterior Cord Syndrome. **Anterior cord syndrome** results from injury of the sensory and motor tracts located in the anterior portion of the cord (Figure 32-4b ■). The posterior portion of the cord, where the tracts for light touch are located, is not injured. The patient can present with the loss of sensation to pain and loss of motor function below the site of cord injury; however, the patient can retain the ability to feel light touch.

ASSESSMENT TIPS

In anterior cord syndrome, the patient loses the ability to feel pain and crude touch below the site of injury and likely experiences the loss of motor function below the injury site. However, the patient retains the ability to feel light touch both above and below the site of injury. ■

Brown-Séquard Syndrome. An injury to a hemisection—the right or left half—of the spinal cord (Figure 32-4c ■) disrupts the spinal tracts on only one side of the cord. The patient experiences motor and sensory losses below the injury site, but the distinctive feature of **Brown-Séquard syndrome** is that the effects differ on the two sides of the body. The patient loses motor function and light touch sensation on one side but loses pain sensation on the opposite side. For example, on the right the patient might not move and feel light touch but can feel pain. On the left, he can move and feel light touch, but he does not feel pain. As you can recall from earlier in the chapter, the pain tracts cross over upon entering the spinal cord and carry the impulse up the opposite side of the cord, but the motor and light touch tracts carry the impulse up the same side as where they entered the cord. This explains the different assessment findings on opposite sides of the body.

ASSESSMENT TIPS

In Brown-Séquard syndrome, the patient loses motor function and light touch sensation on one side of the body while retaining pain sensation on that same side. On the opposite side of the body, the patient retains motor function and light touch sensation while losing pain sensation. ■

A complete spinal cord injury can result in the classic findings: total paralysis and loss of sensation below the level of injury. Any time you get abnormal motor function or sensation results from your assessment, findings that conflict with the classic findings, suspect incomplete cord injury In either case, however, your emergency care must remain the same. Don't confuse inconsistent findings with a patient who is fabricating symptoms for a potential financial gain known as malingering. *The patient who has suffered any spinal cord injury—whether complete or incomplete—requires complete immobilization.*

EMERGENCY CARE FOR SUSPECTED SPINAL INJURY

The proper approach to emergency care for suspected spinal injury is the assessment-based approach, discussed in the next sections.

Assessment-Based Approach: Spinal Injury

Follow the steps of the assessment to identify and provide care for the patient with suspected spinal injury.

Scene Size-Up

Because suspicion of spinal injury is most often based on the MOI, the scene size-up is an extremely important phase of patient assessment.

Likely Mechanisms of Spinal Injury. Be especially alert to the possibility of spinal injury when called to any of the following scenes because all of them are likely to produce the mechanisms that can result in spinal injury:

- Motorcycle crashes
- Motor vehicle crashes
- Pedestrian–vehicle collisions
- Falls
- Blunt trauma
- Penetrating trauma to the head, neck, or torso
- Sporting injuries
- Hangings
- Diving or other water-related accidents
- Gunshot wounds to the head, neck, chest, abdomen, back, or pelvis
- Unresponsive trauma patient
- Electrical injuries

Gunshot wounds to the head, neck, chest, abdomen, back, or pelvis can cause injury to the vertebrae or spinal cord. Even if entrance and exit wounds are closely aligned and appear to indicate a clean, straight-through wound, the bullet could have ricocheted and caused an injury to the vertebrae or spinal cord. Also, exploding fragments from other bones could have injured the spine. With any gunshot wound to the body, you must suspect and assess for possible spinal injury.

According to the National Association of EMS Physicians and the American College of Surgeons Committee on Trauma position statement, "Patients with penetrating trauma to the head, neck, or torso and no evidence of spinal injury should not be immobilized on a backboard." (National Association of EMS Physicians and the American College of Surgeons Committee on Trauma (2013) EMS Spinal Precautions and the Use of the Long Backboard, *Prehospital Emergency Care*, 17:3, 392–393, DOI: 10:3109/10903127.2013.773115) Research has shown a higher death rate for penetrating trauma patients who were immobilized to a backboard as

compared to those who were not. The recommendation in the penetrating trauma patient with neurologic deficit or evidence of spinal injury is to apply a cervical collar and secure the patient to the stretcher. If the patient has no assessment findings consistent with spinal injury, there is no need to do any spine motion restriction.

Also suspect spinal injury with any serious blunt injury to the head, neck, chest, abdomen, back, or pelvis—and even to the legs or arms. The energy of the impact can travel up the extremity to the spinal column. Again, if the patient with blunt injury has no assessment findings consistent with spinal injury and is a reliable patient (alert and oriented, not under the influence of drugs or alcohol, can communicate effectively, and has no other long bone fractures), spine motion restriction is not needed.

Clues to Mechanism of Injury. An MOI heightens your suspicion that a potential injury might have occurred and does not provide any evidence that an injury did occur. Assessment findings provide actual evidence of whether a spinal injury has or has not occurred. Nevertheless, consider the MOI to both heighten your suspicion and ensure that you perform a thorough neurologic assessment. In some cases, such as a patient with an altered mental status who is no longer reliable, you need to take the necessary spinal restriction precautions based on the MOI. However, the practice of providing spinal precautions for all patients with any type of MOI regardless of negative assessment findings is no longer considered a standard practice.

Upon arrival, scan the scene closely for evidence of an MOI that could cause damage to the vertebrae or spinal cord. Look up, down, and around the patient for signs that an injury might have occurred. If an unresponsive patient is lying on the ground near a tree, assume that the patient fell out of the tree until proven otherwise.

Even though there might be no overt signs of trauma to the patient, a spinal injury can nevertheless exist. In such a situation, opening the airway using a head-tilt, chin-lift maneuver (which requires extension of the head and neck) or failing to provide proper spine motion restriction—allowing the patient to move without any restriction—might produce catastrophic permanent injury or even be lethal to the patient. These dire results can be avoided if you perform a thorough assessment of the patient and apply the spine motion restriction that the assessment indicates is necessary.

You must deduce the MOI from the evidence at the scene and determine if such a mechanism could have injured the spine. For example, on arrival at the scene of an automobile collision, you might note damage to the front of the car. As you quickly scan the car, you note an impact mark on the front windshield on the driver's side, apparently made by the driver's head (Figure 32-5 ■). You also note that the patient is not wearing his lap or shoulder restraint and the airbag didn't deploy.

This evidence should create a high index of suspicion that the patient was propelled forward in the crash and struck his head on the windshield. This would likely have caused the head and neck to bend (flex) forward during the forward movement and bend backward (hyperextend) during the rearward movement. Both motions are significant mechanisms of injury that might not be suspected if the damage to the vehicle were not observed.

■ **FIGURE 32-5** Front-end damage and a driver's side windshield fracture indicate that the driver was probably thrown head first into the windshield. (© Ed Effron)

You might arrive at a collision scene and find the patient walking around or sitting in the back of a police car. This does not rule out the possibility of spinal injury, especially an incomplete spinal cord injury or a vertebral injury. Often, a patient with a stable spinal injury does not exhibit signs and symptoms consistent with injury to the spine. However, improper movement by either the patient or the EMT can potentially cause the stable injury to become unstable, resulting in permanent neurologic damage or even death. You must maintain proper spine motion restriction until spinal injury can be ruled out through the assessment, even if the patient has moved prior to your arrival.

Suspicion of injury to the spine or spinal cord is based primarily on the assessment findings and sets the standard for subsequent emergency care for the patient. All assessment and care must be conducted with extreme caution to avoid excessive movement and manipulation of the body. Spine motion restriction must be maintained throughout the entire patient contact if spinal injury is suspected or if it cannot be ruled out.

Primary Assessment

When performing the primary assessment, the general impression might not lead you to suspect a spinal injury because the signs and symptoms might not be apparent. *Regardless of the lack of obvious trauma or patient complaints, you must adopt a high index of suspicion and initiate spine motion restriction if the scene size-up suggests an MOI that could cause spinal injury. Spine motion restriction must be maintained until the patient is secured to a device designed to limit spine movement*

or to the stretcher or until a thorough assessment is conducted and the findings do not indicate a spinal injury. You must follow your local protocols for spine motion restriction.

An important factor to consider in the patient with a possible spinal injury is the mental status. If the mental status is altered, it might be an indication of a head injury, alcohol intoxication, drug influence, shock, hypoxia, or other causes. An altered mental status does not allow the patient to respond adequately to questions or physical assessment or to reliably provide complaints of pain, numbness, tingling, weakness, paralysis, or other signs of neurologic dysfunction. In the case of an altered mental status, the patient's history and physical exam findings are considered unreliable, and you should always assume a spinal cord injury and provide spine motion restriction.

If the patient has other injuries, especially extremity fractures, the pain associated with these injuries might distract from any pain or tenderness the patient experiences to the spinal column. Thus, the patient does not complain of pain to the spinal column, allowing the EMT who is not prudent to miss the possible spinal injury. Be careful not to be drawn away from spinal assessment by other injuries, known as "distracting injuries." Suspect a cervical spinal injury for any patient with injuries above the clavicles (head, face, neck) spinal injury.

Furthermore, if a patient has trouble communicating with you because of a language barrier, deafness, or other reasons, he might not complain of symptoms or respond appropriately to your assessment.

Whenever a spinal injury is suspected, you must open the airway using the jaw-thrust maneuver instead of the head-tilt, chin-lift maneuver. Do not turn the patient's head to the side to facilitate drainage of fluids from the airway. Instead, suction any secretions, blood, or vomitus from the patient's mouth.

Spinal cord damage from a cervical spinal injury can block nerve impulses traveling from the brain to the diaphragm and intercostal muscles, which are necessary for adequate respiration. Inadequate or absent breathing can result. There might be little or no movement of the chest and only slight movement of the abdominal muscles, or you might note excessive abdominal muscle movement. Be prepared to provide positive pressure ventilation with supplemental oxygen.

PATHOPHYSIOLOGY PEARLS

An injury to the cervical spine in the third (C3) to fifth (C5) cervical vertebrae might injure the phrenic nerve that controls the function of the diaphragm. Because the diaphragm provides more than 60 percent of the effort to breathe, the patient can develop respiratory failure and require ventilation. An injury to the spinal cord at this level also eliminates impulses to the intercostal muscles because the nerves that control these muscles exit at the seventh cervical (C7) to first thoracic (T1) vertebrae. ■

The patient's pulse and skin color, temperature, and condition might appear normal with an injury to the vertebrae. However, an injury to the spinal cord can interrupt the transmission of impulses from the brain to the heart and the blood vessels that control blood pressure. You might find the radial pulse weak or absent because of a reduced blood pressure. The skin might be warm and dry below the site of the spinal cord injury and cool, pale, and moist above the site of injury. This is relatively rare.

PATHOPHYSIOLOGY PEARLS

The warm and flushed skin is due to massive vasodilation below the site of injury and the loss of sympathetic tone provided to those vessels, allowing the blood to pool in the vessels in the skin and extremities. ■

ASSESSMENT TIPS

The skin might initially appear flushed and warm in the patient with a spinal injury; however, as the pooled blood begins to deoxygenate and cool, the skin can become mottled and cool. ■

The mental status of a patient with a spinal injury can range from completely alert and oriented to unresponsive.

Based on the assessment findings, categorize the patient as either high or low priority for emergency care or transport. If the patient is unresponsive, is responsive but cannot obey your commands, or displays an abnormal respiratory pattern or obvious signs of spinal injury such as numbness or paralysis, you must consider the patient a high priority for emergency care and prompt transportation to the highest-level trauma center based on your destination proposals.

Secondary Assessment

Conduct the secondary assessment. Continue with spine motion restriction and reassess the patient's mental status. Conduct a physical exam, and then assess vital signs and gather a history.

Physical Exam. If the patient is alert and oriented and can obey your commands, some protocols allow you to instruct the patient to perform **self-restriction**, which is for the patient himself to keep his head, neck, and spine in alignment and to restrict or prevent his movement. You can do so by instructing the patient to bring his head into a neutral in-line position so that his eyes are facing forward, his nose is in line with his umbilicus, and his head or neck is not flexed or extended, rotated, or in a lateral position. He should bring his feet together so that his toes are also in line with his umbilicus and nose. He should maintain this position until after the neurologic assessment where you then either provide further spine motion restriction or his spine will be cleared and

no further spine motion restriction is necessary. Instruct the patient to be still and not attempt to move.

In the patient who is not alert or cannot obey your commands, it might be necessary for an EMT at the scene to provide manual restriction so that the patient doesn't move his head and neck. Do not attempt to unbutton or unzip clothing to expose the patient. Instead, reduce unnecessary movement by cutting clothing away. Conduct a physical exam. Inspect and palpate the head, neck, chest, abdomen, pelvis, extremities, and posterior body for evidence of trauma.

When a spinal injury is suspected, pay attention to the following during the exam:

- **Injuries associated with a spinal injury.** Watch for evidence of trauma to the head, posterior cervical region, anterior neck, chest, abdomen, back, and pelvis. Injuries to these areas also are frequently associated with spinal injury.
- **Cervical collar.** For the patient with an altered mental status or one who cannot obey your commands, or if the patient complains of pain or tenderness to the vertebral column, following your assessment of the neck, apply the cervical collar. For the patient who is self-restricting, the cervical collar should be applied only after the spinal exam is completed and a positive finding is present. There are many hazards and negative effects from the placement of a cervical collar, which are covered later in the chapter. The cervical collar is only an adjunct to spine motion restriction. The primary purpose of the cervical collar is to remind the patient not to move his head and neck; however, it does provide some motion restriction in the upper cervical region.
- **Assess pulses and conduct a neurologic assessment by testing motor and sensory function.** In the responsive patient, check the pulses in all four extremities and conduct a neurologic assessment by testing the motor and sensory function (EMT Skills 32-1) of each extremity. While assessment motor and sensory function is performed, maintain spine motion restriction.

To assess the pulses and motor and sensory function, do the following:

Pulse Assessment in All Four Extremities

- Check for the presence and strength of the radial pulses for the upper extremities, the pedal pulses for the lower extremities.

Motor Function Assessment in the Upper Extremities

To check motor function in the upper extremities, ask the patient to do the following:

- "Flex your arms (bend the arms at the elbows) across your chest" (tests motor function at C6).
- "Extend your arms (straighten the arms to the side of the body)" (tests motor function at C7).
- "Spread your fingers out on both hands and don't let me squeeze them together" (tests motor function at T1).
- "Hold out both arms and don't let me push your hand down" (done while you support the hand under the wrist) (tests motor function at C7).

Motor Function Assessment in the Lower Extremities

To check motor function in the lower extremities, ask the patient to do the following:

- "Push down against my hands with your feet" (place your hands under the feet) (tests motor function at S1 and S2).
- "Pull up against my hands with your feet" (place your hands on the tops of the feet) (tests motor function at the level of L5).

Sensory Function Assessment

A cotton swab with a wooden stick can be used for checking both pain and light touch. Break the stick in half. Use the jagged broken end to test for pain and the soft cotton tip to assess for light touch. If you don't have a swab, you can pinch the skin for pain and lightly touch the skin for light touch.

Test for Pain Perception

Have the patient close his eyes. With the sharp end of the swab's wooden stick, poke one of the hands. When the patient grimaces, moans, or responds in some other way, ask "Where does it hurt?" Repeat the test on the other hand and then on each foot.

Test for Light Touch Perception

Have the patient again close his eyes. Lightly touch the patient's fingers on one hand and then the other. As you perform this test for light touch to the fingers, ask:

- Can you feel me touching your finger?"
- "Can you tell me what hand and which finger I'm touching?"

You would repeat the test on one of the toes on each foot. As you test for light touch on the toes, ask:

- "Can you feel me touching your toe?"
- "Can you tell me which foot and what toe I'm touching?"

If the patient is unresponsive, pinch the foot and hand to determine a sensory response. Compare the sensory function and strength in the upper and lower extremities. It is more common for spinal cord injuries to cause paralysis to all four extremities (*quadriplegia*) or to the lower one-half of the body only (*paraplegia*). Loss of function confined to the right or left side of the body (*hemiplegia*) is more typical of a brain injury or stroke. Conflicting or partial loss of motor or sensory function might be an indication of an incomplete spinal cord injury.

PATHOPHYSIOLOGY PEARLS

Pain applied to an extremity can travel through a nerve tract, enter the spinal cord, and be immediately turned around by a reflex arc and sent back out through a motor tract, causing the patient to move even though the impulse never reached the brain. Thus, the motor response to this *does not* tell you about the integrity of the brain and the nerve tracts, which is what it is intended to do. ■

- **Posterior exam.** Carefully log roll the patient with spine motion restriction maintained to assess the posterior body. Palpate the area of the spine gently. Evidence of deformity, tenderness, contusions, lacerations, punctures, or swelling to the spine or around the spine should heighten your suspicion that a spinal column injury exists. Muscle spasms along the spinal column are a protective reflex and a common indication that a spinal injury has occurred.

Vital Signs. Obtain and record a set of vital signs. If the brain or spinal cord is damaged, vital signs might reflect neurogenic hypotension. The blood pressure can be low and the heart rate normal or bradycardic. The hypotension associated with spinal shock is not usually severe but mild, with a systolic blood pressure usually no lower than 80 mmHg. As noted earlier in the chapter, in spinal shock the skin is warm and dry and the patient presents with motor and/or sensory deficit. Closely reassess the patient for deterioration and report these findings to the emergency department. If the hypotension is severe and the patient has tachycardia, suspect bleeding as the cause of shock and treat accordingly. Hypovolemia and spinal cord injury can both be present in the same patient; therefore, be cautious in your assessment because a spinal cord injury might prevent the typical signs of hypovolemic shock from occurring.

PATHOPHYSIOLOGY PEARLS

The hypotension in spinal shock is due to massive vasodilation and pooling of blood in peripheral vessels. No blood or fluid is lost from the vessels; however, the increase in the vessel size reduces the vessel resistance, blood pressure, and perfusion. This produces a distributive type of shock. ■

ASSESSMENT TIPS

Neurogenic hypotension resulting from vasodilation in a spinal injury rarely produces a systolic blood pressure of less than 80 mmHg. ■

History. Obtain a history from the responsive patient. Because of the seriousness of a spinal injury, try to take this history as the physical exam is conducted. Questions that might be asked in cases of suspected spinal injury include the following:

- Does your neck or back hurt?
- Where does it hurt?
- Can you move your hands and feet?
- Do you have any pain or muscle spasms along your back or to the back of your neck?
- Do you have any numbness or tingling sensations in either of your arms or legs?
- Was the onset of pain associated with a fall or other injury?
- Did you move or did someone move you before our arrival?
- Were you up walking around before our arrival?

Assess for allergies, medications, past medical history, and the last intake of food or drink. Remember to ask about events prior to the onset of signs or symptoms because they might provide evidence of or clarify the MOI.

If the patient is unresponsive, obtain the history from the bystanders at the scene. Try to determine the patient's mental status before your arrival, if the patient moved any extremities, or if the patient was moved prior to your arrival.

Signs and Symptoms. Spine motion restriction should be based on physical assessment findings and not solely on MOI. It is imperative for you to recognize that a patient's lack of pain in the spinal column or his ability to walk, to move his extremities, and to feel sensations does not rule out the possibility of spinal column (vertebral) or incomplete spinal cord injury.

The following are signs and symptoms of a spinal injury (Figure 32-6 ■):

- Tenderness at the injury, specifically along the spinal column.
- Pain associated with movement from spinal injury that might be localized. Ask the patient to pinpoint the location (by telling you where it is, not by trying to point to it). *Do not ask the patient to move to try to elicit a pain response. Do not move the patient to test for pain.*
- Pain independent of movement or palpation along the spinal column or in the lower legs. Such pain is generally intermittent instead of constant and can occur anywhere along the spinal column from the base of the head to the extreme lower back. If the lower spinal column is injured, the patient might complain of pain to the legs.
- Obvious deformity of the spine upon palpation. This is a rare assessment finding.
- Soft tissue injuries. Those from trauma to the head and neck are associated with cervical spinal injury. Soft tissue injuries to the shoulders, posterior thorax (back), or abdomen are associated with thoracic or lumbar spinal injury. Lower extremity trauma is associated with lumbar and sacral spinal injury.
- Numbness, weakness, tingling, or loss of sensation or motor function in any of the arms or legs.
- Loss of sensation or paralysis below the suspected level of injury or in the upper or lower extremities. Paralysis of the extremities is a reliable sign of spinal injury.
- Loss of bowel or bladder control (incontinence).

SIGNS AND SYMPTOMS OF POSSIBLE SPINAL INJURY

• PAIN	Unprovoked pain in area of injury, along spine, in lower legs.
• TENDERNESS	Gentle touch of area may increase pain.
• DEFORMITY (rare)	There may be abnormal bend or bony prominence.
• SOFT TISSUE INJURY	Injury to the head, neck, or face may indicate cervical-spine injury. Injury to shoulders, back, and abdomen may indicate thoracic- or lumbar-spine injury. Injury to extremities may indicate lumbar- or sacral-spine injury.
• PARALYSIS	Inability to move or inability to feel sensation in some part of body may indicate spinal fracture with cord injury.
• PAINFUL MOVEMENT	Movement may increase pain. Never try to move the injured area.
• ALSO:	Loss of bowel or bladder control, priapism, impaired breathing.

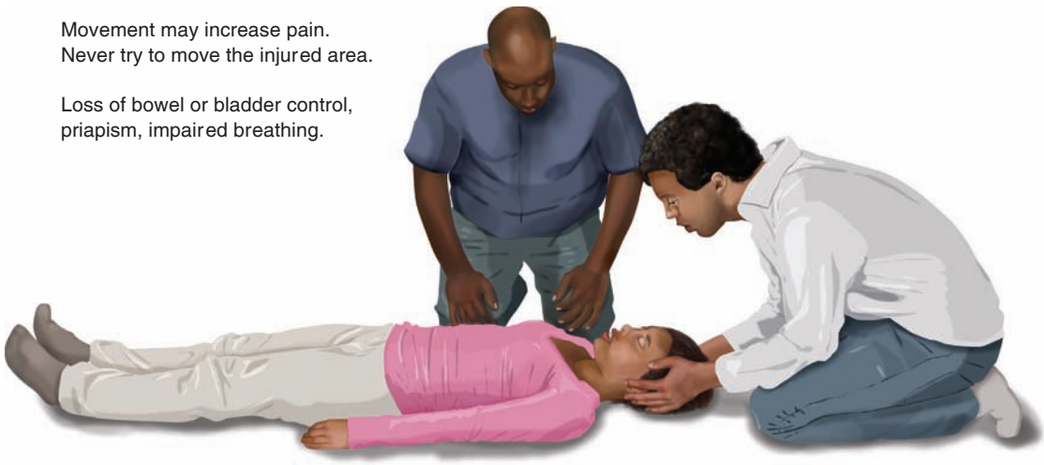

■ **FIGURE 32-6** Signs and symptoms of possible spinal injury.

- Priapism, a persistent erection of the penis resulting from injury to the spinal nerves to the genitals. It occurs soon after injury and is a classic sign of cervical spinal injury.
- Impaired breathing, especially breathing that involves little or no chest movement and only slight abdominal movement. This is an indication that the patient is breathing with the diaphragm alone. Diaphragmatic breathing is indicative of cervical spinal injury. If injury to the nerve that controls the diaphragm occurs, you might see either no breathing effort or an attempt to breathe using only the abdominal muscles.

Indications for Spine Motion Restriction Based on Assessment Findings. The following are indications for transporting a patient with spine motion restriction in blunt and penetrating trauma based on a thorough assessment.

- Glasgow Coma Scale of <15
- Any suspected traumatic brain injury
- Any condition in which the patient has an altered mental status
- Any pain or tenderness along the vertebral column
- Any paralysis (partial or complete), weakness, numbness, or tingling, prickling sensation
- Deformity along the vertebral column
- A patient who has sustained a significant MOI and is under the influence of alcohol or drugs, cannot communicate effectively or understand, or has a painful distracting injury

If any of these indications are found during the assessment, you must provide spine motion restriction throughout the remainder of the assessment, treatment, and transport of the patient. This is true even if the MOI doesn't seem severe enough to have produced a spinal injury.

Complications of Spinal Injury. Spinal injury can produce catastrophic permanent damage. Three major complications of spinal injury follow:

- **Inadequate breathing effort.** Paralysis of the respiratory muscles can occur with an injury to the cervical spine. Rapid deterioration of the patient's condition and death might result without quick intervention by the EMT. The diaphragm might continue to function even if the chest wall muscles are paralyzed. The patient can display shallow, inadequate breathing with little movement of the chest or abdomen. Continuous positive pressure ventilation is necessary.
- **Paralysis.** Paralysis can occur below the site of spinal cord damage. If the damage is to the spinal cord below the cervical region, paralysis is isolated to the

lower half of the body (paraplegia). Damage to the cervical spinal cord can produce complete paralysis of the entire body (quadriplegia or tetraplegia). Paralysis and complete loss of sensation to only one side of the body (hemiplegia) is more common in head injuries and stroke; however, an incomplete spinal cord injury can cause loss of motor and sensory function in different areas of the body.

- **Inadequate circulation.** Blood pressure and perfusion might be poor in the patient with a spinal injury because of spinal shock. If the spinal cord nerve fibers traveling from the medulla in the brain to the blood vessels are damaged, the blood pressure control center (vasomotor center) can no longer maintain the muscle tone in the blood vessels. Below the point of the spinal cord injury, the blood vessels dilate (increase in size) and lower their resistance. Subsequently, blood begins to pool in the dilated vessels, the blood pressure drops, and the perfusion of other tissues of the body is reduced. Because of the blood vessel dilation, the skin is usually warm and dry, even though the tissue perfusion is poor. The heart rate typically remains normal or decreases slightly. In this case, be sure to look for other reasons for the low blood pressure.

ASSESSMENT TIPS

Pain or tenderness along the vertebral column is a significant sign of a possible spinal column (vertebral) fracture. ■

Emergency Medical Care

For a suspected spinal injury, it is not the role of the EMT to diagnose the condition or the site of the injury. The EMT must instead ensure that life-threatening conditions are cared for, that the possibility of further injury is reduced by careful handling of the patient, and that spine motion restrictions are applied and the patient expeditiously transported to a medical facility.

When in doubt, provide and maintain spine motion restriction.

It is safer to err on the side of caution and provide spine motion restriction if spinal injury is suspected. Spine motion restriction devices can always be removed at the emergency department after the physician or radiographic studies determine that no spinal injury exists. Paralysis resulting from failure to provide spine motion restriction because he did not display signs and symptoms of spinal injury cannot be so easily undone.

The general guidelines for emergency care of a patient with a suspected spinal injury are follow:

1. **Take necessary Standard Precautions.**
2. **Have the patient self-restrict or provide manual restriction or stabilization of the head and neck** (EMT Skills 32-2). Ensure that the head is in a neutral, in-line position. That means bringing the head into a position in which the nose is in line with the umbilicus (navel) and the head is neither flexed forward nor extended backward, bent lateral, nor rotated.

   If the patient complains of severe pain to the neck or cervical spine, or the head does not easily move, maintain the head in the position found.
3. **When performing the primary assessment, open and maintain the airway with the jaw-thrust maneuver.** Insert an oropharyngeal or nasopharyngeal airway, if necessary. Suction secretions without turning the patient's head. Provide positive pressure ventilation or supplemental oxygen to maintain an SpO_2 of 94% or greater.
4. **Assess the pulse, motor function, and sensation (both pain and light touch) in all extremities.** Record these and document any differences or changes in the neurologic status during your contact with the patient.
5. **Assess the cervical region and the neck before applying the cervical collar.** Gently palpate the cervical region for any deformities or tenderness.
6. **Apply a cervical collar.** Be sure that you are familiar with the type of cervical collar you are using. Refer to the manufacturer's instructions on proper sizing because each device is different. An improperly sized collar can cause more harm to the patient, compromise the airway, and further aggravate a potential spinal injury. Information about sizing and applying the cervical collar is given on the following pages.

   If the cervical collar does not fit properly, use a rolled towel or blanket instead. Loosely wrap the towel or blanket around the patient's neck to take the place of the cervical collar, taping the towel or blanket to the backboard. Maintain spine motion restriction.
7. **Secure the patient to the stretcher, backboard, vacuum mattress, or scoop stretcher.** Steps for securing the patient in a variety of different circumstances are illustrated and explained on the following pages.
8. **After the patient is secured to the stretcher, reassess, record, and document the pulses and motor and sensory function in all extremities.**
9. **Transport to the hospital.**

Reassessment

Perform a reassessment every 5 minutes en route to the hospital. Ensure that the airway is clear and that breathing is adequate. Reassess and record the vital signs. Look for any changes in the pulse, skin condition, or blood pressure.

Because a spinal injury is rarely an isolated injury, look for signs of hypovolemic shock: The skin becomes pale, cool, and moist; the blood pressure falls; the heart rate increases; and the patient's mental status decreases. Remember that a decreasing level of responsiveness is an early sign of head injury, whereas a rising systolic

blood pressure and decreasing heart rate are late signs of head injury.

If the patient has any further complaints, repeat those necessary parts of the physical exam. Be aware of complaints of tingling, numbness, loss of sensation, or paralysis anywhere in the body. Reevaluate any airway adjuncts, positive pressure ventilation devices, mask seal, oxygen therapy, splints, and immobilization devices. Record your findings in the prehospital care report and communicate them to the emergency department.

Summary: Assessment and Care

To review possible assessment findings and emergency care for injuries to the spine, see Figures 32-7 ■ and 32-8 ■.

GUIDELINES FOR SPINE MOTION RESTRICTION

As an EMT, you will encounter patients with spinal injury or suspected spinal injury in a variety of different circumstances. Some might be lying unresponsive on the ground. Others might be responsive but seated in wrecked automobiles. Still others might be walking about. No matter what the circumstances, your task when you encounter a patient with suspected spinal injury is to protect the spine and spinal cord from further injury. Mastering a variety of equipment and techniques can help you carry out this task successfully.

Historical Perspective: Spinal Immobilization Versus Spine Motion Restriction

Historically, "spinal immobilization" was developed as a procedure to protect the spine and spinal cord from secondary injury associated with movement during extrication and transport. Spinal immobilization procedures were applied in the United States to millions of patients a year who had no known spine or spinal cord injury. Research has found that spinal immobilization techniques and equipment were producing more negative effects and causing more harm to patients than any benefits provided. In addition, it has been realized that it is impossible to truly "immobilize" the spine. However, it is possible to restrict spine motion or movement. Thus, the transition from spinal immobilization to spine motion restriction in protecting the patient's spine and spinal cord from further injury.

Assessment Summary

SPINE INJURY

The following findings may be associated with a spine injury.

Scene Size-Up

Pay particular attention to your own safety. Look for:
- Mechanism of injury
- Automobile crash
- Motorcycle crash
- Pedestrian–vehicle collision
- Fall
- Blunt trauma
- Penetrating trauma to the head, neck, and torso
- Hanging
- Diving accident or submersion incident
- Gunshot wound to head, neck, chest, abdomen, or pelvis
- Electrical injury

Primary Assessment

General Impression
- Assume spinal injury based on mechanism of injury
- Patient may be paralyzed and not moving

Mental Status
- Alert to unresponsive, based on type and degree of injury

Airway
- Assume airway is compromised if patient has an altered mental status

Breathing
- May be absent, inadequate, or normal
- Little or no movement of chest with slight or excessive abdominal muscle use, depending on level of spinal cord injury

Circulation
- Pulse and skin color vary, depending on injury
- Pulse may be normal or decreased
- Skin may be normal, or may be pale, cool, and clammy above site of injury and flushed, warm, and dry below site of injury

Status: Priority patient if evidence of a spinal injury or altered mental status exists

Secondary Assessment

Physical Exam

Head and neck:
- Open or closed wounds to the head, neck, or face

Chest:
- Blunt or penetrating trauma to chest

continued

■ **FIGURE 32-7A** Assessment summary: spinal injury.

continued

Abdomen:
- Blunt or penetrating trauma to abdomen

Pelvis:
- Blunt or penetrating trauma to pelvic area

Extremities:
- No response to pain or light touch
- Inability to move extremities
- Numbness or tingling sensation in extremities

Posterior body:
- Deformity to spinal column
- Evidence of trauma
- Swelling around spinal column
- Tenderness on palpation of spinal column
- Muscle spasms along spinal column
- Blunt or penetrating trauma to back

Vital Signs

BP: normal, or may be low
HR: normal, or bradycardia
RR: normal, irregular, decreased, or absent
Skin: normal, or may be pale, cool, and clammy above site of injury and flushed, warm, and dry below site of injury
SpO_2: 94% or greater unless poor perfusion status or breathing status is affected by cord injury
Pupils: equal and reactive, may be sluggish to respond to light

Note: If the blood pressure is low, heart rate is elevated, and skin is pale, cool, and clammy, suspect hypovolemic shock. Look for other trauma and treat for shock.

History

- Tenderness in area of injury
- Pain
- Deformity to the spine
- Soft tissue injuries to posterior body, neck, or cervical region
- Numbness, tingling, weakness, or paralysis in arms and/or legs
- Loss of bowel and bladder control
- Priapism (persistent erection of penis)
- Inadequate breathing or abnormal breathing patterns

FIGURE 32-7A Assessment summary: spinal injury.

Emergency Care Protocol

SPINE INJURY

1. Establish spine motion restriction.
2. Establish and maintain an open airway. Insert a nasopharyngeal or oropharyngeal airway if the patient is unresponsive and has no gag or cough reflex.
3. Suction secretions as necessary.
4. If breathing is inadequate, provide positive pressure ventilation with supplemental oxygen at a rate of 10–12 ventilations/minute for an adult and 12–20 ventilations/minute for an infant or child.
5. If breathing is adequate, administer oxygen if the SpO_2 is less than 94% or any signs of respiratory distress or hypoxia are present.
6. Control any major bleeding.
7. Apply a cervical collar.
8. Provide spine motion restriction that is necessary and appropriate for that patient.
9. If blood pressure and heart rate are low and skin is flushed below the level of injury, suspect spinal shock with neurogenic hypotension. Treat for shock.
10. If blood pressure is low, heart rate is elevated, and skin is pale, cool, and clammy, suspect hypovolemic shock. Look for other injuries and treat for shock.
11. Transport.
12. Perform a reassessment every 5 minutes if unstable and every 15 minutes if stable. Be prepared for vomiting and seizures.

FIGURE 32-7B Emergency care protocol: spinal injury.

Spinal Immobilization

The standard practice since 1960 for patients with suspected spinal injury based solely on MOI was to perform spinal immobilization using a cervical collar and backboard. Based on a report published in 1966 by Geisler et al., the medical community subscribed to the belief that any patient with blunt force trauma, especially from motor vehicle crashes, should be immobilized on a rigid device to reduce the risk of paralysis resulting from an unrecognized spinal injury. In 1968, Farrington described the procedure of using a cervical collar and long or short backboard as necessary to prevent the head and neck from moving during extrication.

Emergency Care Algorithm SPINAL INJURY

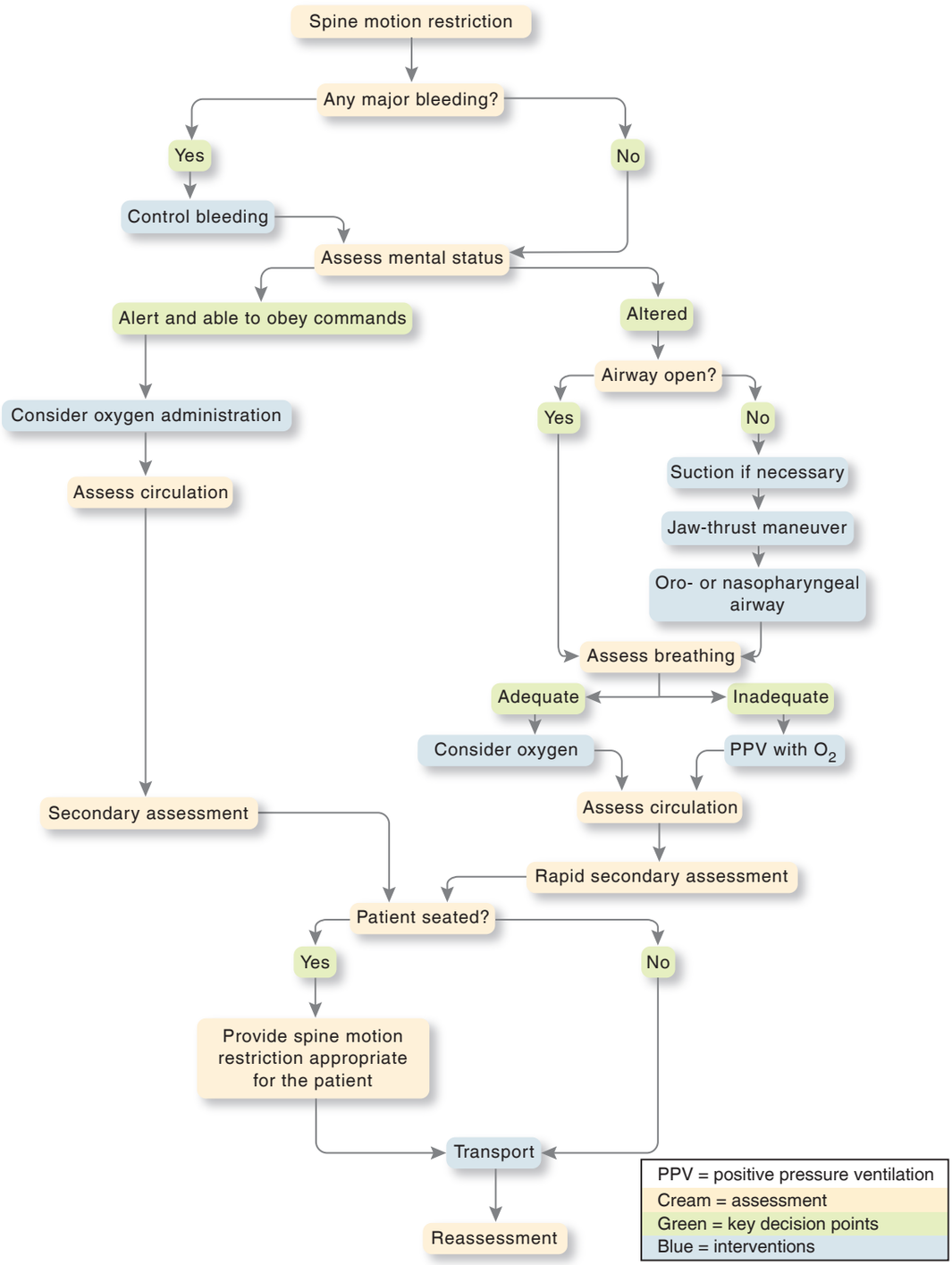

■ **FIGURE 32-8** Emergency care algorithm: spinal injury.

In 1971, the American Academy of Orthopedic Surgeons published one of the first EMS guidelines for applying a cervical collar and securing the patient to a long backboard for a suspected spinal injury to prevent inadvertent worsening of an unstable spinal injury by unnecessary movement. The thought at the time was that the backboard would splint the entire spine and provide immobilization that would protect the patient against any further or secondary spinal injury. In 1979, Bohlman published a report that linked secondary spinal injury from emergency physicians having an underappreciation of movement of patients with spinal injuries. EMS providers were also suspected of have the same underappreciation.

From this concern, therefore, the practice that was implemented was to apply spinal immobilization using a cervical collar and backboard to all patients with suspicion of possible spinal injury based on MOI alone, even if the assessment findings were negative and the patient had no complaints. Subsequently, EMS providers were taught to hold manual stabilization of the head and neck until the patient was placed on a backboard, the head immobilized, and the patient secured by straps to the rigid board. This was the gold standard of "spinal immobilization." The patient or equipment was never removed or released until a physician "cleared the spine."

At the time, the low cost of the devices and equipment, convenience for EMS providers in moving patients, and no perceived negative impact or downside, spinal immobilization became the standard practice for all trauma patients with any MOI that could possibly cause a vertebral or spinal cord injury. It is estimated that up to 5 million patients a year with no evidence of spinal injury received spinal immobilization. The backboard also became a popular and convenient device to move patients regardless of suspected spinal injury.

Spine Motion Restriction

The concept of spine motion restriction (SMR) and its application in prehospital care has its most important roots in statements published by the National Association of EMS Physicians (NAEMSP), the American College of Surgeons (ACS), and the American College of Emergency Physicians (ACEP), as described next.

In 2013, NAEMSP and ACS published the position statement "EMS Spinal Precautions and the Use of the Long Backboard" (National Association of EMS Physicians and the American College of Surgeons Committee on Trauma [2013] EMS Spinal Precautions and the Use of the Long Backboard, *Prehospital Emergency Care*, 17:3, 392–393, DOI: 10:3109/10903127.2013.773115). The following statements were published in the position statement.

- "Long backboards are commonly used to attempt to provide rigid spinal immobilization among emergency medical services (EMS) trauma patients. However, the benefit of long backboards is largely unproven."
- "The long backboard can induce pain, patient agitation, and respiratory compromise. Further, the backboard can decrease tissue perfusion at the pressure points, leading to the development of pressure ulcers."
- "Utilization of backboards for spinal immobilization during transport should be judicious, so that potential benefits outweigh risks."

The position paper describes the patients for whom use of a backboard "might" be used and those for whom the backboard is not recommended. This is covered in more detail in the section" Indications for Spine Motion Restriction." The position paper does state that spinal attention is necessary for at-risk patients, whether or not a backboard is used. It goes on to describe the application of a cervical collar, securing the patient to the stretcher, minimal movement of the patient, and in-line stabilization that should be used during any necessary movement or transfer. The position paper also indicates that if a backboard is used, the patient should be removed from it as quickly as practical in the emergency department.

The ACEP published the policy statement "EMS Management of Patients with Potential Spinal Injury" in 2015 in the *Clinical & Practice Management* publication (https://www.acep.org/Clinical---Practice Management/EMS Management of Patients with Potential Spinal injury/?__taxonomyid=471085). The ACEP policy statement includes the following.

- ACEP stated its belief that efficacy of current practices in out-of-hospital care of patients who may have spinal injuries are not supported by evidence. Rather, current scientific evidence indicates that current spinal injury immobilization and transport practices may be harmful, possibly compromising the airway, impairing respiration, causing aspiration and tissue ischemia, increasing intracranial pressure, and exacerbating pain. These practices may also lead to increased use of diagnostic imaging and even mortality.
- It is impossible to achieve complete spinal immobilization. ACEP recommends spine motion restriction over immobilization attempts. Spine motion restriction aims to maintain anatomic alignment of the spine and to keep gross movement to a minimum. Specific adjuncts are not mandated for spine motion restriction.

ACEP also published a list of patient indications for application of spine motion restriction, which are discussed in the "Indications for Spine Motion Restriction" section.

NAEMSP published "Spine Motion Restriction: An Educational and Implementation Program to Redefine Prehospital Spinal Assessment and Care" in *Prehospital Emergency Care* in 2014 (James F. Morrissey EMT P, MA Elsie R. Kusel EMT-P & Karl A. Sporer MD, FACEP, FACP [2014] Spinal Motion Restriction: An Educational and Implementation Program to Redefine Prehospital Spinal Assessment and Care, *Prehospital Emergency Care*, 18:3, 429–432, DOI: 10.3109/10903127.2013.869643). In the manuscript, the following spine motion restriction (SMR) teaching points summarize the new approach to emergency care of patients with suspected spinal injury in the prehospital setting.

- Do not use mechanism of injury as the sole criteria for spine motion restriction. Assessment findings should guide SMR.
- Differentiate between stable and unstable cervical column injuries.
- Differentiate the multisystem, multitrauma victim from the patient with moderate, low kinetic energy trauma who likely does not require SMR.
- Emphasize the full and complete assessment of the patient before deciding on SMR.
- Omit SMR altogether for those patients who meet the "clearance" criteria.
- Victims of penetrating trauma should not be immobilized unless neurologic deficits are present.
- There is a lack of evidence and potential harm in using an unpadded backboard; therefore, avoid its use.
- Stable spine injuries need little in terms of field stabilization. Application of a cervical collar and securing the patient to the stretcher mattress is usually all that is needed.
- An alternative method of SMR is using a vacuum mattress.
- The SMR method should conform to the patient. You should not make the patient conform to the SMR device.
- When performing SMR, allow patients to be comfortably secured in a variety of positions such as sitting, reclined, or on their side.

Indications for Spine Motion Restriction

The indications for which patients should receive spine motion restriction are based on a variety of sources. It is important to follow your local protocol that might include many of those described in this section. The neurologic assessment that was described earlier and other evaluative criteria are used to "clear the spine" in patients in the prehospital setting. This means that the patient does not have any positive assessment findings that indicate possible vertebral injury (pain, tenderness, or deformity to the spinal column) or spinal cord injury (motor or sensory deficits or abnormal sensations such as tingling or numbness), and the patient is reliable. A reliable patient is one who

- Has a Glasgow Coma Scale score of 15 (the maximum score)
- Does not have a head injury
- Is not intoxicated or under the influence of drugs
- Does not have a distracting injury (long bone fracture, large laceration, or other injury that causes more pain than the vertebral column, if injured)
- Can communicate effectively to understand your questions and provide appropriate responses (does not have communication barriers such as hearing loss or deafness or a language barrier)

A patient who has an MOI that can potentially result in a vertebral or spinal cord injury and who is deemed "not reliable" or "unreliable" for the spinal assessment must be provided with spine motion restriction throughout the call on-scene activities, during transport, and when delivered to the medical facility.

Two of the established criteria that lead to many of the early spinal clearance protocols are the National Emergency X-Radiography Utilization Group (NEXUS) and the Canadian C-Spine Rules (CCR). These criteria were developed to determine which patients with potential spinal injury should receive X-rays in the emergency department. These same criteria were used to develop prehospital spinal clearance protocols. Subsequently, NAEMSP and ACEP also made recommendations for who should get SMR in the prehospital setting. The criteria from all these sources are summarized as follows.

SMR is necessary for patients who meet the following criteria:

- An unreliable patient (GCS <15, altered mental status, head injury, can't communicate effectively, is intoxicated or under the influence of drugs, has a distracting injury)
- Has a neurologic deficit (motor or sensory) consistent with a spinal cord injury or complains of numbness or tingling
- Complains of pain or tenderness anywhere along the vertebral column
- Does not complain of pain to the vertebral column but has a distracting injury
- Has an anatomic deformity to the spinal column on assessment

Other SMR criteria might be required by your local protocol. Some protocols can include motor vehicle crashes with high-energy collision, rollovers, ejection, and pedestrian-vehicle collision.

SMR is <u>not</u> necessary in a patient who meets <u>all</u> the following criteria:

- Normal level of consciousness with a GCS of 15 and is a reliable patient
- No spine tenderness on palpation or complaint of pain anywhere along the vertebral column
- No abnormal or absent neurologic findings (motor and sensory) to include no abnormal sensations such as numbness or tingling
- No distracting injury
- Not intoxicated or under the influence of drugs
- Can understand and communicate effectively

Patients with penetrating injuries to the head, neck, or torso who do not have any neurologic deficits or indication of spinal injury should not be immobilized to a backboard.

Spine Motion Restriction Protocols

Spine motion restriction protocols vary widely across the country. In some areas, SMR for a patient who meets one of the criteria for SMR might be as simple as having the patient perform self-restriction of his head, neck, and body; applying a cervical collar; placing the patient directly on the ambulance stretcher mattress; securing

him with the stretcher straps; and reminding him not to move his head or neck. Some SMR protocols allow the patient to be placed in a Fowler or semi-Fowler position, or a position of comfort on the stretcher.

On the other end of the spectrum of SMR, some protocols still require the patient to be placed on a long backboard with a cervical collar and head stabilization device and strapped securely to the backboard, and the backboard with patient secured to it then placed on the stretcher. The latter SMR procedure has fallen out of favor because of the research that has clearly shown hazards and poor outcomes with the described technique and equipment.

As already noted, spine motion restriction techniques vary widely; they might include any of the following.

- Application of a soft cervical collar and the patient secured to the ambulance mattress.
- Application of a rigid cervical collar and the patient secured to the ambulance stretcher.
- Application of a cervical collar and the patient secured in a vacuum mattress and then placed on the stretcher.
- Application of a cervical collar and the patient lifted and moved to the stretcher using a scoop stretcher. After the patient is moved to the stretcher, the scoop stretcher is removed.
- Application of a cervical collar and the patient lifted and moved to the stretcher using a backboard. After the patient is moved to the stretcher, he is removed from the backboard and placed directly on the stretcher mattress.
- Application of a cervical collar and vest-type device applied to the patient for extrication. The patient is secured to the backboard with the vest-type device in place. The entire backboard with patient is placed on the stretcher.
- Application of a cervical collar and the patient placed on and strapped to a long backboard, the head secured by a head immobilization device. The entire backboard with the patient is placed on the stretcher.

The SMR techniques just listed are covered in more detail later in the chapter in the "Spine Motion Restriction Techniques" section. Follow your local protocol.

Tools for SMR

The basic tools used in spine motion restriction are cervical collars, stretcher mattresses, vacuum mattresses, scoop stretchers, long backboards, head immobilization devices, and vest-type short backboards. Some of these tools are associated with increased risk to the patient and are not recommended for use in some protocols.

Cervical Collars

A cervical collar should be used any time you suspect injury to the spine. There are several types of cervical collars (EMT Skills 32-3) including rigid and soft collars. The primary purpose of the cervical collar is simply to remind the patient to keep his head and neck in a neutral in-line position and not to move. Because awareness has become the primary purpose and because there are hazards associated with the rigid cervical collar, the use of a soft cervical collar, at one time out of favor, is again recommended.

Sizing of the rigid collar to the patient is based on the design of the device (EMT Skills 32-4). Be sure to use a collar of the proper size for the patient.

In a patient who cannot understand or obey your commands, a cervical collar should be applied by two rescuers: One stabilizes the neck manually in the neutral position while the other applies the collar. Placement of the cervical collar should never obstruct the patient's airway. See EMT Skills 32-5, EMT Skills 32-6, EMT Skills 32-7, and EMT Skills 32-8 for detailed descriptions of how to apply a cervical collar.

Hazards of Rigid Cervical Collars. Research has shown that rigid cervical collars, even when sized and placed properly, have risks or produce harmful effects to the patient. Some of these risks or harmful effects follow:

- If not fitted properly, placement of a cervical collar might lead to greater movement of the head and neck.
- Application of a cervical collar and placing a patient with ankylosing spondylitis on a backboard carries an extreme risk of further harm from extension of the cervical spine.
- The cervical collar can increase intracranial pressure. Intracranial pressure is increased even more when the patient is placed supine and then when immobilized to a backboard. This could be detrimental in a patient with a head injury.
- The correct application of a cervical collar can create an unnatural separation of the spine by as much as 11.3 mm. This is enough to cause a secondary spinal injury.
- A cervical collar might increase spinal motion in high cervical spine injuries (C1 through C4).
- The cervical collar can cause separation of C1 and C2 while stretching the spine cord.
- The cervical collar can cause pressure sores to the soft tissue of the neck. This can lead to increased pain and possible infection.
- The cervical collar itself can produce pain and discomfort.
- There is an increase in difficulty in managing the airway with a cervical collar in place. Mouth opening is restricted up to 25 percent. Aspiration is more common if the patient vomits while wearing a cervical collar. The collar might also contribute to a restriction in respiration when used with a backboard.

Because of the many hazards just listed for rigid cervical collars, the soft cervical collar is a viable alternative to the rigid collar. Keep in mind that in the current SMR protocols the real purpose of the cervical collar is simply to remind the patient not to move his head and neck.

Full Body Spinal Restriction Devices

Historically, the standard device used to restrict movement of the entire spinal column was the long rigid backboard.

Long Rigid Backboards

Several types of long-board devices exist to provide restriction of the head, neck, torso, pelvis, and extremities. Techniques have been developed for safely log-rolling and securing a patient onto a long board (EMT Skills 32-9, EMT Skills 32-10, EMT Skills 32-11, and EMT Skills 32-13). These techniques will be described in detail in "SMR for a Supine or Prone Patient to Be Secured to a Long Backboard" in the later section "The Patient Found Supine or Prone." However, rigid backboards are associated with many hazards and harmful effects to patients, as detailed earlier, and the benefit of their use often does not outweigh their harmful effects.

Hazards of Long Rigid Backboards. As already mentioned, there are many hazards and harmful effects associated with placing a patient on a long rigid backboard. Some of the hazards and harmful effects of securing and transporting a patient on a rigid long backboard follow:

- Patients who are immobilized to the backboard in a supine position cannot control their own airway and are prone to aspiration of gastric contents if they vomit.
- The straps that are tightened across the patient's chest have a restrictive effect on breathing and interfere with the mechanics of breathing. There is a reduction in the patient's pulmonary compliance and respiratory volumes that reduce the patient's effectiveness of breathing.
- The rigid board itself can produce pain, especially to the cervical region and lower back, in patients who had no pain before being secured to the backboard.
- Existing pain can be worsened when the patient is placed on a rigid backboard.
- Backboards are commonly stored in outside ambulance compartments. For EMS systems that operate in cold or cool environments, the backboard is often the same temperature as the ambient air outside or in the station bay. Even if it is the temperature of the station bay, it is commonly only 68 to 70 degrees. Placing an exposed trauma patient on a 68 or 70 degree or colder backboard can allow the patient's body through conduction to lose heat to the board. This can cause a reduction in the patient's body core temperature. In the trauma patient who is bleeding, a decrease in body temperature can inhibit clotting, which can result in severe bleeding.
- Pressure sores (decubitus ulcers) can occur from being secured to the rigid backboard. One study found pressure sore development begins soon after the patient is placed on the board and before their arrival at the hospital. One study found that tissue infarct and ulceration occurs with a pressure of 70 mmHg over 2 hours. The typical sacral pressure of a patient who is supine on a long backboard is approximately 233 mmHg and thoracic pressure is 83 mmHg.
- Patients who are placed supine in the back of the ambulance are more likely to experience motion sickness in a moving ambulance, which increases their risk of aspiration if secured to a backboard.

Although there are many harmful effects of backboards, some EMS systems continue to allow their use as part of the SMR protocol. Therefore, techniques to provide spine motion restriction using a backboard are covered later in the chapter.

Alternative Long Devices for Spine Motion Restriction

Many protocols still incorporate the backboard into the SMR procedures. In the latest research, other acceptable devices that can be used to provide adequate restriction of movement of the spine are the stretcher mattress itself, a vacuum mattress (EMT Skills 32-13A), and a scoop stretcher. The long backboard is still considered a good device to use when extricating a patient and moving a patient. Many protocols continue to allow and even advocate for the backboard to be used in these situations; however, prior to transport the patient is taken off the backboard and placed directly onto the stretcher mattress. Current research has found that the securing the patient to the stretcher mattress alone provides spine motion restriction adequate to prevent further injury.

Short Spine Motion Restriction Devices

The most common short spine device is the Kendrick Extrication Device (K.E.D.) (EMT Skills 32-13B). The K.E.D. is one of many commercially made vest-type devices with supplied straps for the head, chest, and legs. This device is now rarely used to provide spine motion restriction. Current research has shown that more manipulation can occur when applying and using these devices as compared to having patients simply extricate themselves from the vehicle while maintaining their own self-restriction of their head and neck. Or the EMS crew can remove the patient using a rapid extrication (rollout) technique, which is covered later in the chapter. Vest-type devices require the addition of backboard straps, padding, tape, or cravats to secure the patient. They require a significant amount of time to apply and are most commonly used to extricate noncritical sitting patients with suspected spine injuries, not critical patients who require rapid transport.

Although these devices are rarely used and the research does not advocate their use, some EMS systems continue to carry the vest-type device, and it might be part of the SMR protocol. Therefore, you need to be familiar with the proper use of these devices to avoid further injury to the patient. For vest-type devices, follow all the manufacturer's instructions about application and use of the device.

Other SMR Equipment

Whenever a patient is placed onto a backboard, he must be secured to the board with straps and some type of head stabilization device commonly called a head immobilizer.

Straps or cravats are placed to keep the patient from sliding up and down or laterally on the board. Place straps across the chest and under the armpits in a manner that does not interfere with the patient's breathing. Place straps across the pelvis and above the patient's knees.

Deceleration straps are another important adjunct to securing the patient. These straps are fastened across the patient's shoulders. They help prevent the patient's torso from sliding up the backboard and compressing the cervical spine when the ambulance slows or stops during transport.

SPINE MOTION RESTRICTION TECHNIQUES

You will encounter patients with suspected spine injuries in a variety of circumstances. The techniques described in the following sections tell you how to use the tools just described to provide spine motion restriction to patients in common prehospital situations: the ambulatory patient, the patient found supine or prone, and the patient seated in a vehicle.

The Ambulatory Patient

If your evaluation indicates that spine motion restriction is needed, you may be able to instruct the ambulatory patient to perform self restriction or, if the patient is unable to do so, you may need to perform steps to provide spine motion restriction for the patient.

Self-Restriction and Assessing an Ambulatory Patient

EMS crews often arrive at the scene of a motor vehicle crash and find the patient out of the vehicle and walking around the scene. Based on the MOI, you should suspect a possible spinal injury. You must quickly conduct an assessment to determine if the patient is reliable and has any indications of a possible spinal injury. If none are found and the patient has no other indications for SMR, spine motion restriction is not required.

When you arrive at the scene and find an ambulatory patient who was involved in a motor vehicle crash or other incident that could have produced a spinal injury, you should perform the following steps (EMT Skills 32-14A to E) to have the patient self-restrict and for you to conduct your assessment.

1. **Instruct the patient to hold his head and neck in a neutral in-line position and not to move it.** When approaching the patient, do so from directly in front of him so that he remains focused forward and doesn't move his head and neck to the side to look at you. Immediately instruct the patient as you approach him to bring his head and neck in an in-line position by lining up his nose with his umbilicus (navel or belly button); not to bend, rotate, extend or flex his head or neck; he should bring his feet and toes together and in line with his umbilicus and nose. You must remind him to stay in that position and not to move unless you instruct him to do so. This procedure is known as **self-restriction**. (EMT Skills 32-14A)
2. **Assess for pain or tenderness.** Ask the patient if he has any pain anywhere to his neck or anywhere along his vertebral column. Palpate the posterior vertebral column gently. Determine if the patient has any tenderness or if you feel any abnormality to the bony structure. (EMT Skills 32-14B)
3. **Assess motor and sensory function in the upper extremities.** With the patient maintaining self-restriction, have him continue to look forward with his arms at his side. Test motor and sensory function in both upper extremities following the neurologic assessment steps previously covered in the Physical Exam section. (EMT Skills 32-14C and D). Also, ask if the patient has any abnormal sensations such as tingling or numbness to the extremities or upper body.
4. **Assess motor and sensory function in the lower extremities.** Test motor and sensory function in both lower extremities following the neurologic assessment steps previously covered in the Physical Exam section. (EMT Skills 32-14E) Also, ask if the patient has any abnormal sensations such as tingling or numbness to the lower extremities or lower body.

   If the patient is reliable (GCS 15, no distracting injury, can communicate, not intoxicated or under influence of drugs); has no pain, tenderness, or abnormality to the vertebral column; and the patient has no motor or sensory deficits or abnormal sensations; the spine has been "cleared," and there is no need for any further spine motion restriction procedures. The patient should be instructed to relax and he can freely move. If he is to be transported, he could be placed directly on the stretcher mattress in a position of comfort.

Performing SMR for an Ambulatory Patient

If you find the ambulatory patient is not reliable; or has pain, tenderness or abnormality to the vertebral column; has a motor or sensory deficit; or has any abnormal sensations (numbness, tingling); spine motion restriction must be applied to prevent movement of the spine. You would perform the following steps (EMT Skills 32-15A to F):

1. **The patient is kept in a standing position, maintains self-restriction, and a cervical collar is applied.** Instruct the patient to maintain self-restriction while your partner applies a cervical collar. Your protocol might allow the use of a soft or a rigid collar. (EMT Skills 32-15A)

2. **Have the patient sit back onto the stretcher.** Bring the stretcher to the patient and not the patient to the stretcher. Continue to coach the patient to maintain self-restriction. Have your partner move the stretcher directly behind the patient and stabilize it to prevent it from moving. Have your partner guide the patient from behind as you instruct him to sit directly down onto the stretcher. (EMT Skills 32-15B)
3. **Have the patient lift his legs up onto the stretcher.** With self-restriction maintained, have the patient lift his legs up onto the stretcher. You can assist if necessary. Your partner can guide and support his upper torso. The patient does the movement and the EMTs guide and facilitate his movements unless the patient requires assistance. (EMT Skills 32-15C and D)
4. **Have the patient lie back onto the stretcher.** You should now position yourself at the foot of the stretcher so that you can instruct the patient and he can look directly at you and not to the side. Instruct the patient to maintain self-restriction and gently lie back onto the stretcher mattress. Your partner can guide the patient back and provide support to the torso if necessary. (EMT Skills 32-15E).
5. **Secure the patient to the stretcher.** Instruct the patient to remain in a supine position and to maintain self-restriction the entire time until instructed otherwise at the medical facility. Some protocols might allow the patient to be placed in a seated or reclined position or in a position of comfort. Secure the patient to the stretcher with the stretcher straps. (EMT Skills 32-15F)

The Patient Found Supine or Prone

The following equipment and techniques were previously commonly used and might still be used in some SMR protocols today.

SMR for a Supine or Prone Patient to Be Secured to a Long Backboard

When you encounter a supine or prone patient with a suspected spinal injury, first ensure that all life-threatening situations have been managed; establish and maintain in-line manual spinal stabilization or have the patient self-restrict if he can do so; and apply a cervical collar. Then secure the patient to a long backboard, using the four-rescuer log roll and spine motion restriction procedures. (Review EMT Skills 32-9 and EMT Skills 32-10.)

1. **Move the patient onto the long backboard by log rolling the patient.** This move is ideally performed by at least four rescuers. One rescuer at the patient's head directs the movement and maintains in-line stabilization of the patient. One to three other rescuers move the patient onto the backboard. As the patient is rolled onto his side, his posterior body should be carefully assessed if this has not been done during the primary assessment.
2. **Position the long backboard under the patient by sliding the board under the patient during the log roll.** Then place the patient on the board at the command of the rescuer who maintains in-line stabilization. Use a slide, proper lift, log roll, or scoop stretcher to position the patient on the backboard so that movement is as limited as possible. (The method used depends on the situation, scene, and available resources.)
3. **Place padding in the spaces between the patient and the board.** In an adult, pad under the head and torso, taking care to avoid extra movement. In an infant or child up to approximately 8 years, pad under the shoulders (because the child's relatively larger head otherwise can cause the neck to flex forward) and anywhere along the length of the body as necessary to maintain a neutral position.
4. **Secure the patient's torso to the board with straps.** The strap across the chest should be tight enough to prevent shifting of the torso but not so tight that it inhibits movement of the chest muscles and impairs breathing.
5. **Secure the patient's head to the board with a commercial head/cervical stabilization device or using blanket rolls and tape.** Never place padding behind the neck. If the patient vomits, your strapping technique should be good enough to enable you to roll the patient onto his left side several times without any change in body position on the board.
6. **Secure the patient's legs to the board with straps.**
7. **Proceed with care as described earlier under "Emergency Medical Care."**

   If fewer rescuers are available, the log roll can be done by three or two rescuers. (Review EMT Skills 32-11 and EMT Skills 32-12.)

SMR for a Supine or Prone Patient with the Backboard as a Movement Device Only

Many protocols do not advocate or even allow the EMS provider to use a backboard with the exception to extricate the patient from the vehicle and to move the patient to the stretcher. In this case, where the backboard is used only to transport the patient to the stretcher, you would do the following. Keep in mind that a neurologic assessment has already been preformed and a cervical collar would have already been applied to the patient. Either the patient is self-restricting or an EMT is maintaining stabilization of the head and neck in a neutral in-line position.

1. **Logroll the patient onto the backboard** as described previously.
2. **The patient might self-restrict if he is alert and can obey commands,** or an EMT might stabilize his head and neck in a neutral in-line position during the procedure.
3. **Secure the patient to the backboard.**
4. **Move the patient to the stretcher.**

5. **Place the backboard onto the stretcher** and then unsecure the straps.
6. **Instruct the patient to keep his toes and nose lined up with his umbilicus and not to move.** Slide the backboard out from underneath the patient.
7. **Secure the patient to the stretcher mattress** using the stretcher straps.

The Patient Seated in a Vehicle

The patient seated in a vehicle may be able to perform self-extrication or may require a rapid extrication procedure. Less commonly, a procedure that was once common, using a vest-type device, may be performed depending on local protocols.

Note: Research has found that there is less manipulation of the spine when the patient extricates himself as compared to EMS attempting to do so.

SMR and Self-Extrication from a Vehicle

If you arrive on the scene and the patient is still sitting in the motor vehicle or as often found in the back of police car and has no serious injury or life threat found during the primary assessment, you can do the following steps to have the patient self-extricate from the vehicle. Be sure the patient is reliable and has no injury that would be aggravated or would prevent him from effectively self-extricating. If there is any question regarding the patient's ability to self-extricate, you should perform the extrication in a similar manner as the rapid rollout covered later in the chapter. The steps to conduct the self-extrication follows (EMT Skills 32-16A to F):

1. **Instruct the patient to hold his head and neck in a neutral in-line position and not to move it.** When approaching the patient, attempt to do so directly in front of him so that he remains focused forward and doesn't move his head and neck to the side to look at you. Immediately instruct the patient as you approach him to self-restrict by bringing his head and neck in an in-line position by lining up his nose with his umbilicus (navel or bell button); not to bend, rotate, extend, or flex his head or neck; bring his feet and toes together and in line with his umbilicus and nose. You must remind him to stay in that position and not to move unless you instruct him to do so. (EMT Skills 32-16A)
2. **Assess for pain or tenderness.** Ask the patient if he has any pain anywhere to his neck or anywhere along his vertebral column. Palpate the posterior vertebral column gently. Determine if the patient has any tenderness or if you feel any abnormality to the bony structure.
3. **Assess motor and sensory function in the upper extremities.** With the patient maintaining self-restriction, have him continue to look forward with his arms at his side. Test motor and sensory function in both upper extremities following the neurologic exam steps previously covered in the chapter. (EMT Skills 32-16B)
4. **Assess motor and sensory function in the lower extremities.** Test motor and sensory function in both lower extremities following the neurologic exam steps previously covered in the chapter.
5. **The patient maintains self-restriction and a cervical collar is applied.** Instruct the patient to maintain self-restriction while your partner applies a cervical collar. This might be done with the EMT in the backseat or from the side of the vehicle depending on access and where the patient is located inside the vehicle. Your protocol might allow the use of a soft or rigid collar. (EMT Skills 32-16C)
6. **Instruct the patient to pivot his legs and body so that he can bring his legs outside of the vehicle and onto the ground while he remains in a seated position.** With one EMT at the vehicle door entrance facing the patient, instruct the patient to slowly pivot and swivel his body as one unit while maintaining self-restriction and to bring his legs outside of the vehicle until his feet are together on the ground. The patient will now be facing the EMT at the vehicle door entrance. (EMT Skills 32-16D)
7. **Instruct the patient to stand straight up.** The EMT facing the patient now instructs him to stand straight up out of the vehicle and face him while maintaining self-restriction. Assistance could be provided to the patient; however, let the patient do most of the movement. The second EMT should retrieve the stretcher and position it perpendicular and directly in front of the patient. Bring the stretcher to the patient and not the patient to the stretcher. He should not be required to walk to the stretcher unless a safety issue requires him to do so. (EMT Skills 32-16E)
8. **Have the patient rotate 180 degrees and then sit directly back onto the stretcher.** Instruct the patient to maintain self-restriction and rotate 180 degrees until his back faces the stretcher. Have the second EMT, who should now be positioned on the opposite side of the stretcher as the patient, prevent the stretcher from moving and guide the patient back onto the stretcher mattress. (EMT Skills 32-16F)
9. **Have the patient lift his legs onto the stretcher and then lie back into a supine position.** This procedure is done in two motions. First, have the patient lift his legs and bring them onto the stretcher. You can assist the patient in bringing his legs up if necessary. Then, with your partner guiding the patient's torso and movement back, have the patient lie back onto the stretcher mattress. Again, some protocols allow the patient to be placed in a seated, reclined, or position of comfort. Follow your local protocol.

10. **Secure the patient to the stretcher.** Using the stretcher straps, secure the patient to the stretcher. Remind the patient to maintain self-restriction until he is told not to any longer by a medical professional at the medical facility he has been transported to.

SMR for a Seated Patient Using a Vest-Type Device

Although the technique and equipment described here—using a vest-type device—is uncommon today, it is still found in some EMS protocols. More commonly, now, if the patient is alert enough and can do so, he might be instructed to self-extricate, as described in the preceding section. If the patient cannot self-extricate, the rapid rollout procedure is usually used to remove the patient, as described in the next section.

When considering use of a vest-type device to extricate a seated patient from a vehicle, keep in mind that the current research has found that less manipulation of the spine is done when the patient moves himself out of the vehicle. In addition, this procedure is time-consuming and should never be done on a patient with any physiologic instability, evidence of hypovolemia or shock, or any head, chest, abdominal, pelvic, femur, or multiple fractures.

If the patient with a suspected spinal injury is in a seated position, a short spine motion restriction device might be used if your local protocols permit.

The following are general steps. The steps for using a vest-type device are illustrated in EMT Skills 32-17A to 17H.

1. **Use manual in-line spinal stabilization and apply a cervical collar.** Assess pulses and motor and sensory function in all four extremities. (EMT Skills 32-17A and 17B)
2. **Position the short spinal device behind the patient.** Examine the back carefully. Be careful that the EMT who is holding in-line spinal stabilization does not move excessively or move the patient as the device is positioned. You should slide the board behind the patient and as far into the seat as you can. The top of the board should be level with the top of the patient's head, and the bottom of the board should not extend past the coccyx. The body flaps should fit snugly under the patient's armpits. (EMT Skills 32-17C)
3. **Secure the device to the patient's torso.** Make sure the straps are tight enough to prevent movement of the device laterally or vertically. If the device has straps that circle the legs, apply and tighten these after the chest straps are applied. (EMT Skills 32-17D and 17E)
4. **Pad behind the patient's head to ensure neutral alignment of the head and neck with the remainder of the spine.** Excessive padding causes the head and neck to flex forward, whereas lack of padding allows the head and neck to be extended.
5. **Secure the patient's head to the device.** Maintain manual in-line spinal stabilization even though the head is secured to the device. Securing the head is the last step in the application of the device. (EMT Skills 32-17F)
6. **Position a long backboard under or next to the patient's buttocks and rotate him until his back is in line with the backboard.** Tie the hands together and pivot the patient onto the backboard while maintaining manual in-line spinal stabilization. If it is not possible to get a long backboard next to the patient, lift the patient under his arms and legs and lower him onto the long board. (EMT Skills 32-17G and 17H)
7. **Follow the guidelines for securing a patient to a long backboard.** Release manual in-line spinal stabilization only when the patient is completely secured to the backboard. Assess pulses and motor and sensory function and record your findings on the prehospital care report.
8. **Proceed with care as described earlier under "Emergency Medical Care."**

There are several special considerations to be aware of when using a short spinal device:

- Perform any assessment of the back, scapula, arms, or clavicles before you apply the board.
- Angle the board to fit between the arms of the rescuer who is stabilizing the patient's head without jarring the rescuer's arms.
- As already mentioned, push the spine board as far down into the seat as possible. If you don't, the board might shift and the patient's cervical spine might compress. The top of the board must be level with the top of the patient's head; the base of the board must not extend past the coccyx.
- Never place a chin cup or chin strap on the patient. They prevent the patient from opening his mouth if he needs to vomit.
- When applying the first strap to the torso, take care not to apply the strap too tightly, which could cause abdominal injury or impair breathing.
- Always tighten the torso and leg straps before securing the patient's head to the device. This prevents accidental movement of the patient's cervical spine.
- Never allow buckles to be placed midsternum where they would interfere with proper hand placement if CPR becomes necessary.
- Never pad between the cervical collar and the board; doing so creates a pivot point that might cause hyperextension of the cervical spine when the head is secured.
- Assess pulses and motor and sensory function before and after applying the device.

Rapid Extrication (Rapid Rollout)

There are times when you must move a patient with a suspected spinal injury before securing him to a long backboard or even to a short spinal device. The three situations in which such movement is permissible follows:

- The scene is not safe (because of the threat of fire or explosion, chemical spills, or gunfire, for example).

- The patient's condition is so unstable that you need to move and transport him immediately.
- The patient blocks your access to a second, more seriously injured patient.

In these circumstances—when the time saved by immediate extrication might make the difference between life and death—a *rapid extrication, also know as a rapid rollout,* is performed. Rapid extrication emphasizes the need for rapid movement of the patient with stabilization of the spine maintained. Time is critical in the situations just described; therefore, the benefit of rapid transport outweighs the risk of applying other type of SMR equipment during extrication.

Rapid extrication requires constant cervical spine stabilization and good communication among the EMTs moving the patient. The patient's entanglement with seat belts, wreckage, or other objects can complicate rapid extrication procedures, so all rescuers need to be aware of the patient's position as well as any potential problems as the extrication is proceeding.

In rapid extrication, the patient is brought into alignment with manual in-line spinal stabilization and a cervical collar is applied. A long backboard is positioned next to him. The patient is quickly transferred to the long backboard while manual in-line spinal stabilization is maintained. The rapid extrication procedure is described in more detail in EMT Skills 32-18A to 18D.

The rapid extrication technique requires EMTs to improvise at the scene based on the type of car, location of the roof support posts, console between the seats, and size of the patient. If time, resources, and patient condition permit, removal of the roof can enable better access to the patient and easier removal using the rapid extrication technique, as illustrated in EMT Skills 32-18E and 18F.

SPECIAL CONSIDERATIONS

Handling and providing spine motion restriction for patients with suspected spine injuries can be complicated by a variety of factors. Two of the more common situations you can encounter involve suspected spinal injury in people wearing helmets and suspected spinal injury in infants and children.

Helmets

Activities such as bicycle riding, motorcycle riding, and playing sports such as football, hockey, and lacrosse can easily lead to accidents that can produce spinal injury. People taking part in such activities often wear helmets, and you might arrive at an accident scene to encounter a patient still wearing a helmet. Thorough assessment of a patient is difficult under any circumstances; the presence of a helmet makes the task difficult. But removal of a helmet should not be an automatic step. Such removal could risk aggravating the spinal injury, if one exists. You should first assess the patient wearing the helmet in the following areas:

- Assess the patient's mental status and ability to obey commands.
- Assess the patient's airway and breathing.
- Assess the fit of the helmet and the likelihood of movement of the patient's head within the helmet.
- Determine your ability to gain access to the patient's airway if intervention should be necessary to assist his breathing.

You should *leave the helmet in place* if your assessment reveals the following:

- The helmet fits well, and there is little or no movement of the patient's head inside the helmet.
- No impending airway or breathing problems exist.
- Removal of the helmet would cause further injury to the patient.
- You can properly immobilize the spine with the helmet in place.
- The helmet doesn't interfere with your ability to assess and reassess airway and breathing.

You should *remove the helmet* if your assessment reveals the following:

- The helmet interferes with your ability to assess or reassess airway and breathing.
- The helmet interferes with your ability to adequately manage the airway or breathing.
- The helmet does not fit well and allows excessive movement of the head inside the helmet.
- The helmet interferes with proper spinal immobilization.
- The patient is in cardiac arrest.

Helmet Removal

There are two basic types of helmets: sports helmets (such as those worn for football, hockey, and lacrosse) and motorcycle helmets. Typically, sports helmets have an opening in the front and allow easier access to the airway. Face masks on football helmets can be removed either by cutting the plastic clips that hold the mask to the helmet or by unsnapping the face mask retainers. Motorcycle helmets, however, generally cover the full face and have a shield that prevents access to the airway.

The techniques for the removal of motorcycle and sports helmets are illustrated in EMT Skills 32-19 and EMT Skills 32-20. The general steps for removal of a helmet follow:

1. Take the patient's eyeglasses off before you attempt to remove the helmet.
2. One rescuer should stabilize the helmet by placing hands on each side of the helmet with fingers on the mandible (lower jaw) to prevent movement.
3. A second rescuer should loosen the chin strap.
4. The second rescuer should place one hand anteriorly on the mandible at the angle of the jaw and the other hand at the back of the head.

5. The rescuer holding the helmet should pull the sides of the helmet apart (to provide clearance for the ears), gently slip the helmet halfway off the patient's head, and then stop.
6. The rescuer who maintains stabilization of the neck should reposition, sliding his hand under the patient's head to keep the head from falling back after the helmet is completely removed.
7. The first rescuer should remove the helmet completely.
8. The patient should then be immobilized as described earlier.

Equipment-Intensive Sports (Football, Hockey, and Lacrosse) Injuries

Often, sporting events are covered by certified athletic trainers (ATs). ATs receive skills training in sport-related spinal injuries that can differ slightly from the skills training that EMTs receive. If an AT is present, it is important that the AT and EMT are prepared to work together to ensure the athlete receives the best quality care.

If there is not an AT present, the EMT must be prepared to handle a situation that might involve unfamiliar sports equipment. When dealing with equipment-intensive sports such as football, hockey and lacrosse, the EMT must take into consideration the equipment these athletes wear. If there is no AT present, the EMT is responsible for equipment removal.

In most cases, this involves an injured football player who wears not only a helmet but also shoulder pads. Typically, the shoulder pads and the helmet elevate the player's head, neck, and shoulders off the ground, almost in a neutral position. Because of this, you should leave the helmet on the player until it is necessary to remove it. Removing the helmet while leaving the shoulder pads on can cause the head to drop and hyperextend the neck. Independent removal of the helmet or shoulder pads is *not* recommended because it compromises spinal alignment.

In the past, it was recommended that the helmet and shoulder pads be left in place for transport and removed at arrival to the emergency facility. New recommendations now state that, when appropriate, helmets and shoulder pads should be removed before transport for an athlete with a suspected cervical spinal injury. This rationale for equipment removal is due to advances in sporting equipment technology, and removing this equipment expedites the athlete's care. Another reason why this equipment should be removed before transport is that the AT and EMT often have more experience with equipment removal than other medical team members or hospital and emergency department staff.

Helmet and shoulder pad removal should be performed by a minimum of three trained rescuers. If, initially, there are fewer than three trained rescuers on hand, equipment removal should take place immediately when more trained rescuers arrive.

The first step is removal of the face mask. According to the Inter-Association Task Force for Appropriate Care of Spine-Injured Athletes, the face mask of the helmet should be removed at the earliest possible point and before transportation. Face mask removal permits immediate access to the airway and removes barriers to providing positive pressure ventilation if necessary. Always remember that the face mask should be removed any time a spinal injury is suspected, regardless of the mental status and airway or respiratory status of the patient.

Removal of the Face Mask. If you are expected to respond to or you are on standby at sports events such as football games, you must have the proper tools to remove the face mask of the helmet in the quickest way with the least amount of movement (EMT Skills 32-21A to 21C).

Several types of tools, such as the FM extractor, Trainer's Angel, knives, pruning shears, and PVC pipe cutters, can be used to remove the face mask. A cordless, powered screwdriver is the recommended tool to use because it is generally quicker and produces less head movement than cutting tools such as the Trainer's Angel or pruning shears. If it is impossible to remove screws because of poor maintenance of the helmet, a back-up cutting tool should be used to cut through the plastic clips that secure the face mask to the helmet. A regular screwdriver is *not* recommended to take off the face mask. Unscrewing the clips causes excessive movement of the head, especially if the screws have been in place for some time and are rusted. DuraShears, EMT shears, and a seat belt cutter are also not recommended because these tools take too much time to cut the plastic clips.

The face mask of the helmet is usually secured by four plastic loop-clips or loop-straps that are screwed into the helmet. Using the cordless, powered screwdriver to remove the screws in the helmet, or by cutting the plastic straps or clips, the face mask can be completely removed. This allows the EMT complete access to the airway for assessment and intervention.

A common practice has been to cut the side clips or straps and lift or "peel" the face mask upward. By this method, the face mask is said to be "retracted" or "swung away." This is no longer recommended because the process causes excessive movement of the head and neck. It is now recommended that all four clips or straps be cut and the face mask completely lifted off the helmet.

If the face mask cannot be removed in a reasonable amount of time, the helmet should be removed in the safest way possible. A neutral in-line spinal position must be maintained during and after the process of safely removing the helmet.

SMR for the Player. The Inter-Association Task Force for Appropriate Care of Spine-Injured Athletes continues to advocate the use of a rigid long backboard, cervical collar, and head stabilization device in spine motion restriction of a suspected spinal injured athlete.

One EMT or AT must maintain in-line spinal stabilization by grasping the helmet and holding the head and

neck in a neutral in-line position. If there is an AT on site who is holding in-line stabilization when the EMT arrives, it is recommended that the AT maintain in-line spinal stabilization until the athlete is completely secured to the long backboard after the face mask is removed, assessment and any immediately required emergency care, for example of the airway, is completed, helmet and shoulder pads removed, and cervical collar applied.

The helmet, chin straps, and pads should initially be left in place while a second EMT removes the face mask. Equipment removal must be done by those with the highest level of training. When removing the helmet and shoulder pads, the helmet must be removed first. As the helmet is removed, an object such as a rolled-up towel should be placed beneath the head to maintain spinal alignment until the shoulder pads are removed. The EMT or AT maintaining spinal alignment must keep his hands on the sides of the head and fingers on the mandible to prevent any motion.

The first steps to removing the shoulder pads require cutting through the athletic jersey with scissors to expose the underlying padding. There is a lot of variation in shoulder pads, so any straps holding the shoulder pads in place need to be removed or cut, and any lacing holding the shoulder pads together must be cut with scissors. The shoulder pad straps should be cut completely to pull them apart. Two rescuers independent of the rescuer maintaining spinal alignment are needed to remove the shoulder pads. One rescuer should be on each side of the athlete to pull the pads apart after they have been cut.

When all equipment has been removed, a cervical collar should be applied. Following application of the cervical collar, the athlete should be lifted onto the long backboard.

For an athlete in a supine position, a lift-and-slide technique, called the eight-person lift, is recommended to move the patient onto the long backboard. As the EMT or AT maintaining spinal alignment holds the head stable, one rescuer should be at each shoulder, one at each hip, one at each lower leg/foot, and one person in place to slide the long backboard under the athlete while the other rescuers lift. The eight-person lift should be directed by the EMT or AT maintaining spinal alignment. It is recommended that all rescuers perform a controlled lift using a count-down method directed by the EMT or AT at the head. All rescuers must lift at the same time to minimize any motion of the spine. The rescuer sliding the long backboard must slide the board when directed by the EMT or AT to maintain spinal alignment. For an athlete in a prone position, the log roll technique must be performed by the rescue team prior to performing the eight-person lift.

When the athlete is on the backboard, straps must be applied to secure the chest, pelvis, and lower extremities above the knees. The torso must be completely secured to the backboard, but the hands and arms should be kept free to facilitate further assessment and treatment techniques. Acceleration/deceleration straps should be used to reduce movement during braking and acceleration of the ambulance. The head should be secured to the backboard to prevent movement. Any gaps between the patient and the backboard should be filled in with towels, pillowcases, or other padding.

SMR in Infants and Children

According to NAEMSP, the incidence of spinal injuries in the pediatric population is lower than in adults. In patients 8 years of age or older, the adult assessment and indications for spine motion restriction can be used. In children less than 8 years of age, if any MOI suggests possible spinal injury, it is prudent to provide spine motion restriction appropriate for the young child. The size of the head of younger patients makes neutral positioning of the head and neck difficult with a standard backboard. The pediatric patient's torso and lower extremities need to be padded adequately to elevate them to the level of the head to achieve a neutral in-line position of the neck.

When treating infants or children, use a rigid board appropriate for the child's size, following the guidelines outlined earlier for general immobilization. However, the following special considerations should apply when providing SMR for infants or children:

- Pad from the shoulders to the heels of an infant or a child, if necessary, to maintain neutral in-line immobilization. The larger head of the infant or young child usually up until 8 years of age causes the head and neck to flex when supine. Use padding behind the shoulders and upper back to eliminate flexion and maintain neutral alignment of the head, neck, and spine.
- Make sure the cervical collar fits properly before applying it to an infant or child. If you don't have a collar that fits, immobilize the neck with a rolled towel, tape the towel to the backboard, and manually support the patient's head in a neutral in-line position. An improperly fitted collar will do more harm than good.

Extrication from a Car Seat

If you are at an automobile collision involving a child in a car seat, *you cannot use that car seat to stabilize the child for transport*. Car seats involved in crashes might have lost the integrity of the structure and might not provide protection to the child if another crash were to occur. Transfer the child to a backboard. If a child needs to be extricated from a car seat for treatment, follow the steps shown in EMT Skills 32-22.

EMT SKILLS 32-1 Neurologic Assessment of Motor and Sensory Function

■ **32-1A** Assess flexion.

■ **32-1B** Assess extension.

■ **32-1C** Assess finger abduction.

■ **32-1D** Assess finger adduction.

■ **32-1E** Assess the wrist and hand.

■ **32-1F** Assess plantar flexion.

■ **32-1G** Assess dorsiflexion.

■ **32-1H** Assess pain response in the hand.

■ **32-1I** Assess pain response in the foot.

■ **32-1J** Assess light touch response in the hand.

■ **32-1K** Assess light touch response in the foot.

■ **32-1L** Assess flexion of the great toe on the same foot.

EMT SKILLS 32-2 Establish Manual In-Line Motion Restriction

■ **32-2A** Properly position your hands.

■ **32-2B** Keep the head in a neutral position and the nose in line with the patient's navel.

EMT SKILLS 32-3 Cervical Collars

(a)

(b)

(c)

(d)

■ **32.3A** Four types of rigid cervical collars. **(a)** STIFNECK SELECT; **(b)** Philadelphia Cervical Collar; **(c)** WIZLOC Cervical Collar; **(d)** NEC-LOC rigid extrication collar.

■ **32-3B** As an alternative to the rigid collar (but for the same purpose, which is to remind the patient not to move his head) a soft cervical collar might be applied.

EMT SKILLS 32-4 Sizing a Cervical Collar

■ **32-4A** To size a cervical collar, first draw an imaginary line across the top of the shoulders and the bottom of the chin. Use your fingers to measure the distance from the shoulder to the chin.

■ **32-4B** Check the collar you select. The distance between the sizing post (black fastener) and lower edge of the rigid plastic should match that of the number of stacked fingers previously measured against the patient's neck.

■ **32-4C** Assemble and preform the collar.

EMT SKILLS 32-5 Applying a Cervical Collar to a Seated Patient

■ **32-5A** After selecting the proper size, slide the cervical collar up the chest wall. The chin must cover the central fastener in the chin piece.

■ **32-5B** Bring the collar around the neck and secure the Velcro. Recheck the position of the patient's head and collar for proper alignment. Make sure the patient's chin covers the central fastener of the chin piece.

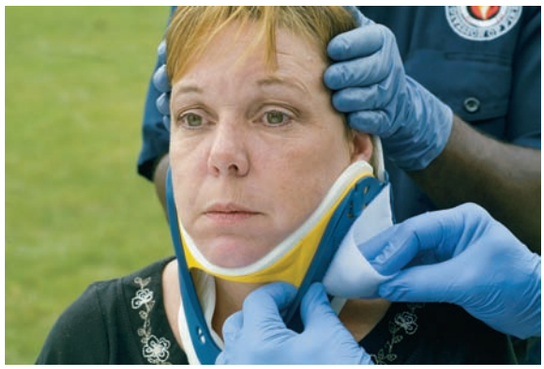

■ **32-5C** If the chin is not covering the fastener of the chin piece, readjust the collar by tightening the Velcro until a proper sizing is obtained. If further tightening will cause hyperextension of the patient's head, select the next smaller size.

EMT SKILLS 32-6 Applying a Cervical Collar to a Supine Patient

■ **32-6A** Slide the back portion of the cervical collar behind the patient's neck. Fold the loop Velcro inward on the foam padding.

■ **32-6B** Position the collar so that the chin fits properly. Secure the collar by attaching the Velcro.

■ **32-6C** Hold the collar in place by grasping the trachea hole. Attach the loop Velcro so it mates with (and is parallel to) the hook Velcro.

EMT SKILLS 32-7 Applying an Adjustable Collar to a Seated Patient

■ **32-7A** Stabilize the head and neck from the rear.

■ **32-7B** Properly angle the collar for placement.

■ **32-7C** Position the collar bottom.

■ **32-7D** Set the collar in place around the neck.

■ **32-7E** Secure the collar.

■ **32-7F** Maintain manual stabilization of the head and neck.

EMT SKILLS 32-8 Applying an Adjustable Collar to a Supine Patient

■ **32-8A** Kneel at the patient's head and stabilize the head and neck.

■ **32-8B** Set the collar in place.

■ **32-8C** Secure the collar.

■ **32-8D** Continue to manually stabilize the head and neck.

EMT SKILLS 32-9 Four-Rescuer Log Roll and Spine Motion Restriction Using a Backboard

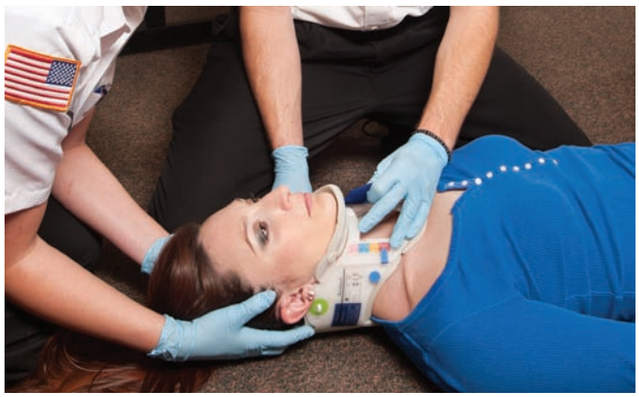

■ **32-9A** Establish and maintain in-line stabilization. Apply a cervical collar.

■ **32-9B** Place a long spine board parallel to the patient. If possible, pad the voids under the head and torso.

■ **32-9C** Three rescuers kneel at the patient's side opposite the board, leaving space to roll the patient toward them.

■ **32-9D** The EMT at the head directs the others to roll the patient as a unit onto his side. Assess the patient's posterior side.

■ **32-9E** The EMT at the waist reaches over, grasps the spine board, and pulls it into position against the patient. (This can also be done by a fifth rescuer.) The EMT at the head instructs the rescuers to roll the patient onto the spine board.

■ **32-9F** Secure the patient to the board with straps. Loosely tie the wrists together.

■ **32-9G** Using a head/cervical stabilization device, secure the patient's head to the spine board.

■ **32-9H** Transfer the patient and the spine board as a unit. Secure the patient and the spine board to the cot.

EMT SKILLS 32-10 Securing a Patient to a Long Board

■ **32-10A** Apply straps to secure the patient to the backboard. Place one strap at the level of the chest, one at the hip, one above the knee, and another below the knee. Pad between the legs.

■ **32-10B** An "X" strap method secures the torso to the backboard. Also, apply one strap at the hip, one above the knee, and one below the knee.

■ **32-10C** A "spider" strap method with Velcro straps.

■ **32-10D** Secure the patient's head to the backboard with a head stabilization device (cardboard disposable device shown).

■ **32-10E** Disposable head stabilization device (Styrofoam disposable device shown).

■ **32-10F** Blanket rolls and tape can be used.

EMT SKILLS 32-11 Three-Rescuer Log Roll

■ **32-11A** Maintain in-line spinal stabilization while preparing for the log roll.

■ **32-11B** Roll the patient onto the side at command of the EMT maintaining stabilization. Inspect the back.

■ **32-11C** Move the spine board into place.

■ **32-11D** Lower the patient onto the spine board at command of the EMT maintaining in-line stabilization. Center the patient on the board.

EMT SKILLS 32-12 Two-Rescuer Log Roll

■ **32-12A** Maintain an open airway and in-line spinal stabilization while applying a cervical spine immobilization collar.

■ **32-12B** Maintain in-line support while moving the patient onto the side.

■ **32-12C** Pull the board against the patient.

■ **32-12D** Roll the patient gently onto the board and secure.

EMT SKILLS 32-13 Examples of Spine Motion Restriction Devices

(a)



(b)

■ **32-13** **(a)** Full body vacuum splint. (© Ferno Corporation); **(b)** K.E.D. (Kendrick Extrication Device)

EMT SKILLS 32-14 Assessment for Spinal Injury in an Ambulatory Patient

■ **32-14A** Instruct the patient to hold her neck and head in line with her umbilicus and to keep her toes and lower body also in line with her nose and umbilicus.

■ **32-14B** Palpate the posterior vertebral column for abnormalities or for tenderness.

■ **32-14C** Assess motor function in the upper extremities.

■ **32-14D** Assess sensory function in the upper extremities.

■ **32-14E** Assess motor and sensory function in the lower extremities.

EMT SKILLS 32-15

Spine Motion Restriction in an Ambulatory Patient

■ **32-15A** Stand directly in front of the patient and instruct her to self-restrict while a second EMT applies a properly sized cervical collar.

■ **32-15B** Instruct the patient to sit straight back onto the stretcher as a second EMT guides her movement and stabilizes the stretcher in place so that it does not move.

■ **32-15C** Instruct the patient to lift her legs onto the stretcher while keeping her body in an in-line position. Assist with the movement of the patient's legs if necessary. A second EMT will support the patient's torso. The EMTs are only facilitating and guiding the patient.

■ **32-15D** The patient's legs should be on the stretcher and her upper body upright and in a seated position.

■ **32-15E** EMT positions herself at the foot of the stretcher directly in front of patient and instructs her to lie straight back onto the flat stretcher mattress. A second EMT guides the patient back as she moves into a supine position on the stretcher.

■ **32-15F** Secure the patient to the stretcher by applying the stretcher straps.

EMT SKILLS 32-16 Spine Motion Restriction in Self-Extrication from a Motor Vehicle

32-16A EMT stands in front of the vehicle and instructs the patient to keep his head and neck straight and to line his nose with his umbilicus and to bring his feet also in line with his nose and umbilicus.

32-16B Assess sensory and motor function in upper and lower extremities.

32-16C Assess the posterior vertebral column for tenderness and abnormality. Then, apply a cervical collar.

32-16D Instruct the patient to swivel his body and to pivot to bring his legs outside of the vehicle until his upper body is facing outside of the vehicle and his feet are on the ground.

32-16E Stand directly in front of the patient and instruct him to get out of the vehicle in one movement while maintaining self-restriction.

32-16F Instruct the patient to sit straight back onto the stretcher while maintaining self-restriction. A second EMT secures the stretcher so it does not move and guides the patient's torso as he moves back to sit down onto the stretcher. Secure the patient to the stretcher.

EMT SKILLS 32-17

Spine Motion Restriction of a Seated Patient with a Ferno K.E.D. Extrication Device

32-17A The Ferno Kendrick Extrication Device (K.E.D.). One EMT gets into the back seat and holds manual stabilization while the other EMT assesses motor and sensory function and pulses.

32-17B After the EMT in the back seat applies a cervical collar, slip the K.E.D. behind the patient and center it.

32-17C Properly align the device. Then, wrap the vest around the patient's torso.

32-17D When the device is tucked well up into the armpits, secure the chest straps.

32-17E Secure the leg straps.

32-17F Secure the patient's head with the Velcro head straps.

32-17G Tie the hands together.

32-17H Pivot the patient onto the backboard while maintaining in-line stabilization. After moving the patient to the backboard, reassess motor and sensory function and pulses in all four extremities.

EMT SKILLS 32-18 Rapid Extrication

32-18A Bring the patient's head into a neutral in-line position. This is best achieved from behind or to the side of the patient. Perform a primary assessment and a rapid physical exam. Then, apply a cervical collar.

32-18B Support the patient's thorax. Rotate the patient until her back is facing the open car door. Bring the patient's legs and feet up onto the car seat.

32-18C Bring the board in line with the patient and against the buttocks. Stabilize the cot under the board. Begin to lower the patient onto the board.

32-18D Lower the patient onto the board. Depending on the structure of the car, it might be necessary to change positions to maintain in-line stabilization while lowering the patient onto the board.

32-18E If the structural features of the vehicle, time, resources, and the patient's condition permit, it might be worthwhile to remove the roof before performing a rapid extrication.

32-18F Depending on variables such as the vehicle's structure and the patient's condition, a rapid extrication might be performed more easily and safely if the roof has been removed.

EMT SKILLS 32-19 Helmet Removal

32-19A One rescuer applies stabilization by placing hands on each side of the helmet with fingers on the patient's mandible to prevent movement.

32-19B A second rescuer places one hand on the mandible at the angle of the jaw.

32-19C With the other hand, the second rescuer holds the occipital region. This maneuver transfers the stabilization responsibility to the second rescuer.

32-19D The rescuer at the top begins to remove the helmet, pulling the sides apart to clear the ears and allowing the second rescuer to readjust his hand position around the mandible and under the occipital region.

32-19E Throughout the removal process, the second rescuer maintains in-line stabilization from below to prevent head tilt.

32-19F After the helmet has been removed, the rescuer at the top replaces his hands on either side of the patient's head with palms over the ears, taking over stabilization.

32-19G Stabilization is maintained from above until a cervical collar is applied and the patient is secured to the backboard.

EMT SKILLS 32-20 Helmet Removal—Alternative Method

32-20A Apply steady stabilization with the neck in neutral position.

32-20B Remove the chin strap.

32-20C Remove the helmet by pulling out laterally on each side.

32-20D Apply a suitable cervical collar and secure the patient to a long board.

EMT SKILLS 32-21 Removing a Football Helmet Face Mask

32-21A Take manual in-line stabilization and remove the mouthpiece.

32-21B If a drill is not available to unscrew the screws, cut the clips that secure the face mask.

32-21C Remove the face mask by lifting it straight off the helmet.

EMT SKILLS 32-22 Extrication from a Child Safety Seat

32-22A EMT #1 stabilizes the car seat in an upright position and applies manual stabilization to the child's head and neck. EMT #2 prepares equipment, and then loosens or cuts the seat straps and raises the front guard.

32-22B A cervical collar is applied to the child as EMT #1 maintains manual stabilization of the head and neck.

32-22C As EMT #1 maintains manual stabilization, EMT #2 places the child safety seat on the center of a backboard and slowly tilts it into supine position. The EMTs are careful not to let the child slide out of the safety seat. For a child with a large head, place a towel under the area where the shoulders will eventually be placed on the board to prevent the child's head from tilting forward.

32-22D EMT #1 maintains manual stabilization and calls for a coordinated long axis move onto the backboard.

32-22E EMT #1 maintains manual stabilization as the move onto the board is completed with the child's shoulders over the folded towel.

32-22F EMT #1 maintains manual stabilization as EMT #2 places rolled towels or blankets on both sides of the child.

32-22G EMT #1 maintains manual stabilization as EMT #2 straps or tapes the child to the board at the level of the upper chest, pelvis, and lower legs. *Do not strap across the abdomen.*

32-22H EMT #1 maintains manual stabilization as EMT #2 places rolled towels on both sides of the head, and then tapes the head securely in place across the forehead and cervical collar. *Do not tape across the chin to avoid pressure on the neck.*

Chapter Review

SUMMARY

Spine injuries could lead to permanent damage to the spinal cord that results in paralysis and loss of sensation below the level of injury. Thus, it is imperative to assess for and manage the patient appropriately to reduce any risk of further injuring the spine or spinal cord. A patient might have a spinal column (vertebral) injury with no spinal cord involvement. Improper management by EMS could convert the spinal column injury into a spinal cord injury. If you have any indication that the patient has suffered a spinal injury, whether it is to the cord or to the column, take the necessary precautions and provide efficient and effective spine motion restriction.

A multitude of signs and symptoms can occur from a spinal injury. An injury to the vertebrae typically produces pain or tenderness along the spinal (vertebral) column. An injury to the spinal cord usually produces motor or sensory deficits. Complications of spinal injury can include inadequate breathing effort, paralysis, and poor perfusion. Beware of confusing assessment findings, which can be an indication of an incomplete spinal cord injury.

Use the proper techniques and equipment to protect the spine and spinal cord from further injury. Spine motion restriction should be applied to any patient suspected of having a spinal column or spinal cord injury.

Case Study Follow-Up

Scene Size-Up

You are dispatched to a gymnastics meet for a 12-year-old girl who has fallen during the competition. As you arrive on the scene, you are directed into the gymnasium by an assistant. The lights are bright and the music is loud. You and your partner make your way around various pieces of gymnastics equipment to the far side of the gym, where a small group of girls, some in tears, are crowded around a young girl supine on the mat. Immediately above her are a set of uneven parallel bars at approximate heights of 10 and 6 feet. A woman, who identifies herself as the coach, is kneeling next to the girl and holding her head and body still. The coach says, "She missed a maneuver off the top bar. She fell and hit the bottom bar with the middle of her back, and then she landed head first on the floor."

Primary Assessment

Recognizing the MOI, your partner immediately brings the patient's head and neck into a neutral position and establishes manual in-line spinal stabilization. You and your partner introduce yourselves and instruct the patient not to move. The young girl cries out, "My legs are numb and tingly! Am I going to be paralyzed?" You ask, "Can you tell me your name?" She says, "Carrie." "Well, Carrie," you say, "We're going to take good care of you and get you to the hospital where the doctors can figure out what's wrong and treat it."

Carrie's airway is patent and her breathing is rapid but adequate at a rate of approximately 28 per minute. ***(The rapid respiratory rate is likely a result of the sympathetic nervous system response to Carrie's anxiety and fear. The adequate tidal volume is an indication that the phrenic nerve is not involved in any cord damage.)*** Her radial pulse is strong and estimated at a rapid 125 per minute. Her skin is slightly cool to touch, slightly pale, and dry***. (Her tachycardia and skin signs are likely due to the sympathetic discharge related to her anxiety and fear. If the she had a higher level spinal cord injury, you would suspect the heart rate to be much slower, possibly bradycardia, and the skin to be red or flushed and warm and dry form the vasodilation.)*** You note, however, that the gymnasium temperature is relatively cool. You apply a pulse oximeter and obtain a reading of 98% on room air; therefore, you determine the oxygenation status to be adequate and do not apply oxygen.

Secondary Assessment

You ask the coach if she saw the accident. You also ask if the patient attempted to get up or if she moved or was moved after the fall. The coach explains that she was standing next to Carrie when she fell. Because of how she landed, the coach immediately went to her side and instructed her to keep extremely still.

You proceed with a physical exam. Very gently, you assess the head and find a contusion along the scalp line above the right eye. You ask, "Carrie, does your neck or back hurt?" She cries, "I don't know. I just feel my legs are numb and tingly." ***(A complaint of numbness or tingling is a positive sensory assessment finding for a possible spinal cord injury.)*** As you carefully palpate her neck, Carrie complains of tenderness to the cervical region at about the level of the sixth vertebra. ***(Tenderness to the vertebral column is another positive assessment finding. Tenderness is typically related to vertebrae that are fractured or dislocated.)*** You apply a cervical collar. The chest, abdomen, and pelvis have no signs of injury.

Following your inspection and palpation of her arms and determining that radial pulses are present bilaterally, you ask, "Can you move your hands just very slightly for me?" The patient complies and waves her hands slightly. You encourage her, "That's very good, Carrie." Keeping your hand out of her sight, you touch the little finger of her left hand and ask, "Can you tell me which hand and finger I'm touching?" Carrie replies, "My left hand, the pinkie." You touch her right hand and she again replies correctly. You then apply pinches to both hands and she identifies them correctly. Finally, you have her grip your fingers simultaneously and find the strength to be equal and strong in both upper extremities. Both radial pulses are strong.

You then inspect and carefully palpate the lower extremities for any signs of injury. The pedal pulses are present bilaterally. You instruct her to wave her foot very gently. She can move both feet. You touch the big toe on the right foot and ask, "Can you tell me which foot and toe I am touching?" She cries, "No!" ***(Loss of sensation to light touch can indicate that one of the posterior columns or other that carries the sensation of light touch from the lower left extremity might have been partially injured. This would be on the left side of the spinal cord, as light touch impulses are carried up the same side of the cord as the sensation. The spinal cord tract carrying motor impulses and pain appear to be intact and not injured.)*** Stabilizing the leg to avoid unsuspected and exaggerated movement, you pinch the top of the left foot. Carrie states, "I can feel that on my left foot." You repeat the same on the right foot and get a response to the pinch.

You enlist the help of the coach, who is familiar with log rolling, and instruct her to position herself at Carrie's feet. You position the backboard next to the patient. At the direction of your partner holding in-line stabilization at Carrie's head, you log roll her up and quickly assess her back, finding no deformities but some tenderness in the lumbar region. The backboard is positioned under her and she is rolled back onto it. A void behind the lumbar region is padded and straps are applied to the torso and legs and secured. A head/cervical stabilization device is applied and secured. Your partner releases manual in-line spinal stabilization and moves to the side to take the baseline vital signs. The blood pressure is 104/76 mmHg, the heart rate is 118 bpm, and the skin is slightly cool to touch, slightly pale, and dry. You obtain a history from the patient.

Case Study Follow-Up

Carrie's parents have been notified by the gym staff. You and your partner meanwhile transfer Carrie to the ambulance and begin transport.

Reassessment

During the reassessment, you reevaluate the spinal immobilization. All straps are secure and all pads properly positioned. Carrie complains of some discomfort to her back but says it is from the hard backboard. You reassess her pulses and motor and sensory function in all the extremities and find no change. You reassess and record the vital signs.

Upon arrival at the emergency department, you help the hospital staff gently transfer the backboard to the emergency department bed. You provide an oral report regarding your findings. You briefly reassure Carrie, and then you proceed to the EMS room to complete your prehospital care report as your partner restocks the ambulance. You finally notify dispatch that you are prepared for another call.

Later that day, on another call to the same hospital, you find time to check on Carrie's condition. The emergency medicine physician states that she suffered a spinal contusion and will completely recover. He praises the coach's work in keeping Carrie still until EMS arrived. He thanks you and your partner for the very detailed information provided both orally and in the prehospital care report regarding the scene characteristics and MOI. He also states, "Very nice immobilization job."

IN REVIEW

1. Describe the relationship between the spinal column and the spinal cord.
2. Name the most common mechanisms of spinal injury.
3. List the signs and symptoms of potential spinal injury.
4. Explain the types of spine motion restriction that must be applied in cases of suspected spinal injury.
5. Describe how the airway is managed in a patient with suspected spinal injury.
6. Explain the purpose and use of the cervical collar.
7. Explain how to assess motor and sensory function in a patient with suspected spinal injury.
8. Explain the use of long and short spine motion restriction devices for seated patients with suspected spine injuries.
9. Under what circumstances is rapid extrication appropriate?
10. Under what circumstances should you leave a helmet in place in a patient with suspected spinal injury?
11. Describe the patient presentation in a complete spinal cord injury.
12. Describe the patient presentation in an incomplete spinal cord injury.
13. Explain how you would instruct your patient to self-restrict.
14. Describe the process of providing spine motion restriction to an ambulatory patient.
15. Describe the process for self-extrication from a motor vehicle while providing spine motion restriction.

CRITICAL THINKING

You arrive on the scene and find an elderly patient who is complaining of severe weakness to her upper extremities. She is alert and responding appropriately to your questions. Her respirations are 22/minute with a good tidal volume. Her radial pulse is present at a rate of 92 bpm. Her skin is warm and dry. Her SpO_2 is 95% on room air. The patient states that she fell while coming down the stairs and struck her face on the floor. You note a contusion to the bottom of her chin. She is also complaining of pain to her neck and cervical region of the spine. She has a history of arthritis and atrial fibrillation. She takes Coumadin for the atrial fibrillation. She last ate approximately 20 minutes prior to her fall. She denies getting dizzy or light-headed or passing out. Her fall was caused by tripping over her slipper.

The patient's pupils are equal and reactive to light. Her anterior and posterior neck areas are tender. No deformities are noted. Her breath sounds are equal and clear bilaterally. Her abdomen is soft and nontender. Her pelvis is stable. Her radial pulses are present. She has severe weakness in the upper extremities, but she is moving her lower extremities with no problem. Her blood pressure is 168/88 mmHg, heart rate 92 and irregular, respirations 22.

1. What initial emergency care would you provide to the patient?
2. What would you assess in your neurologic exam of the patient?
3. Based on the presentation, what type of spinal cord injury do you suspect?
4. What other assessment findings would confirm the type of spinal injury suspected?
5. How would you manage the spinal injury?